

## RESEARCH ARTICLE

## Open Access Journal



# Assisted Therapy with Vacuum and Floating Stoma: A New Way to Treat a Peristomal Abscess

Andriun Duarte Pérez<sup>1\*</sup> | Daniela Mendez Valle<sup>2</sup> | Laura Camila García Medina<sup>3</sup> | Rosa Angélica Osorio Burgos<sup>4</sup> | José Daniel Sierra Reyes<sup>5</sup> | Oscar Ivan Avendaño Solano<sup>6</sup> | Jorge Julian Mendoza Anguila<sup>7</sup> | María Fernanda Riaño Rojas<sup>8</sup>

<sup>1</sup>General Physician, Universidad del Sinú, Montería, Colombia

<sup>2</sup>General Surgery Resident, Universidad de Costa Rica

<sup>3</sup>General Physician, Universidad de los Andes, Bogotá

<sup>4</sup>General Physician, Universidad del Sinú, Montería

<sup>5</sup>General Physician, Fundación Universitaria Juan N Corpas, Bogotá

<sup>6</sup>General Physician, Corporación Universitaria Remington, Colombia

<sup>7</sup>General Physician, Universidad Cooperativa de Colombia, Sede Santa Marta

<sup>8</sup>General Physician, Fundación Universitaria de Ciencias de la salud. FUCS, Bogotá

### Abstract

An ostomy or stoma is the opening created surgically between a hollow viscus and the skin of the anterior abdominal wall, somewhat different from the floating stoma which is defined as a stoma characterized by the absence of fixation of this to the skin of the abdominal wall. These therapies have multiple variants that generate positive impacts and some situations in which negative effects can be observed in patients with complications of peristomal abscesses. The formation of a peristomal abscess is a rare condition, it generally occurs in 10% to 25% of cases of complications and is related to parietal inoculation or contamination of a peristomal hematoma. It has been described that the “floating stoma” therapy plus the vacuum therapy present in ostomized patients has had positive results as a therapy to treat patients who, in addition to being ostomized, have complications such as peristomal abscess, in fact, after the revision Bibliographic studies ensure that these can completely resolve peristomal abscesses, control, drain, correct and even allow faster closure of the abdominal wall, which is why it has been used as an effective therapy.

Keywords: Floating stoma, peristomal abscess, therapy, surgical procedure, open abdomen, ostomy

Copyright : © 2021 The Authors. Published by Medical Editor and Educational Research Publishers Ltd. This is an open access article under the CC BY-NC-ND license

(<https://creativecommons.org/licenses/by-nc-nd/4.0/>).

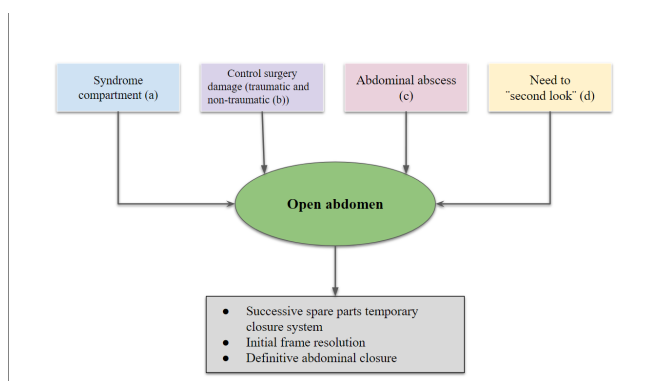


## 1 | INTRODUCTION

**A**n ostomy or stoma is the surgically created opening between a hollow viscus and the

## ASSISTED THERAPY WITH VACUUM AND FLOATING STOMA: A NEW WAY TO TREAT A PERI-STOMAL ABSCESS

skin of the anterior abdominal wall that results in the external diversion of stool or urine and can be permanent or temporary (1). The global incidence of ostomy and peristomal skin complications is estimated to be around 50% (2). However, a floating stoma is defined as a stoma but with a particular characteristic and that is that it is not attached to the skin of the abdominal wall (3). Undoubtedly, this open abdomen surgical method is a technical resource that the surgeon can use in selected cases in different settings, as shown in Figure 1 (4). In short, it is a treatment that, although it is highly effective and has the ability to save lives, behaves like a physical and mental aggression that affects the body integrity, functional capacity and quality of life of the patient, generating a great impact on the daily life of the same (5). There are about 1.5 million patients with intestinal ostomies in the United States, and 100,000 new ostomies are performed annually, of which 51% are colostomies, 35% ileostomies, and 12% ostomies. However, the products of these techniques associated with intestinal bacterial flora, generally tend to drastically change the skin and subcutaneous tissue, causing from skin contact injuries, superinfection, to collections in deep planes such as abscesses (6).



**FIGURE 1:** Algorithm 1 for open abdomen indications

**Supplementary information** The online version of this article ( <https://doi.org/10.52845/JMRHS/2021-4-12-4> ) contains supplementary material, which is available to auto-rized users.

**Corresponding Author:** *Andriun Duarte Pérez*  
General Physician, Universidad del Sinú, Montería, Colombia

Taken from Boza, Ana Senent, Virginia María Durán and Felipe Pareja Ciuró. "UNIT 16: OPEN ABDOMEN. INDICATIONS AND ASSOCIATED COMPLICATIONS". Collaborating Entity: 247.

Among the complications of an ostomy, the most commonly described are: retraction, hernias, prolapses, necrosis and alterations of the peristomal skin and even the formation of abscesses due to infection (7). For this reason, these therapies usually have perspectives that, although they can be positive, they can also be negative, such as the fact of triggering abscesses as a result of possible infections, however, these same therapies can solve this problem by showing the positive part of your use as an efficient alternative. Periosteal abscesses occur in 10% to 25% of cases of complications and are related to parietal inoculation or contamination of a peristomal hematoma, such contamination usually occurs due to poor hygiene and poor preparation of the treated or generally ostomized area in Although in the early postoperative period of this population, periosteal infections and abscesses are relatively rare, with a reported incidence between 2% and 14.8% (8). However, although they are infrequent, the possibility of looking for alternatives to reduce their prevalence is not ruled out, therefore, authors have mentioned that it is more beneficial to keep the ostomy loop closed since avoiding its opening for 24 hours allows the intestine to adhere to the wall reducing the possibility of contamination, in fact, this measure has emerged as a way to avoid these complications and are part of a preventive treatment. Additionally, among the characteristics of using techniques such as floating stoma or vacuum therapy, there is a wide range aimed at a correct management of the scenario in question, among those characteristics and advantages of open abdomen therapy is the possibility of continuously inspecting the abdominal viscera, provides information on the fluids that are collected from the abdominal cavity, allows continuous drainage of the peritoneal cavity in the most homogeneous way possible, among others that can be observed in table 1 (3) (4).

### Table 1. Characteristics of the use of open abdomen devices.

As can be seen in figure 1, one of the scenarios that have been described and that can trigger the use

Inspection continuous abdominal viscera
Provide information on fluids that are collected from the abdominal cavity
Allows a quick and easy access to the peritoneal cavity for reexploration
Allows continuous drainage of the peritoneal cavity of the form more homogeneous possible
Accurately measures the pressure exerted over the abdominal cavity

**FIGURE 2:**

of vacuum therapy and floating stoma is abdominal abscess, this is due to the fact that thanks to this surgical intervention previously performed on the patient It is possible to treat, inspect, and collect information from the abscess in a faster way, due to all the characteristics and advantages that this technique presents. In fact, studies assure that a vacuum-assisted therapy and floating stoma are a good way to manage cavities. Complicated periosteal lesions, as it allows the abscess to be drained, correcting dead space and retraction, without the need for general anesthesia or surgery rooms, avoiding perioperative risks, prolonged medical treatment, exhaustion and frustration of the surgical team, then, In other words, it can be affirmed that the “floating stoma” plus vacuum therapy can resolve total periosteal abscesses, control sepsis, correct retraction, loss of dead space (periosteal pockets) and even allows faster closure of the abdominal wall (3) (9) (10).

## 2 | MATERIALS AND METHODS

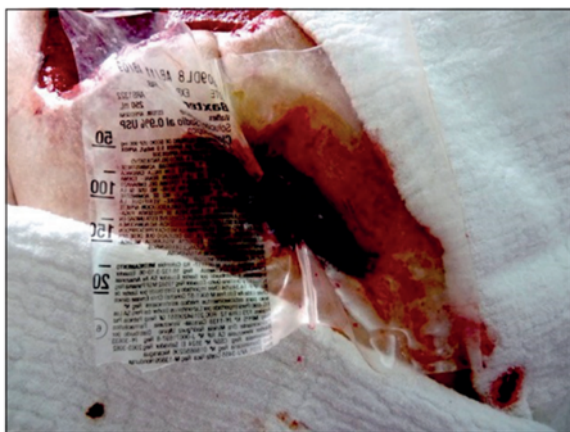A detailed bibliographic search of the most relevant published information is carried out in published databases, scielo, medline, national and international libraries specialized in the topics covered in this review article. The following descriptors will be used: floating stoma, peristomal abscess, therapy, surgical procedure, open abdomen, ostomy. The data obtained oscillate between 5 and 20 records after the use of the different keywords. The search for articles was carried out in Spanish and English, was limited by year of publication and will be used in studies published from 2010 to the present.

## 3 | RESULTS

A limited number of articles that met the inclusion criteria were identified for the development of the research. We found that ostomies are artificial communications of a hollow intraperitoneal organ with the abdominal wall, which have the purpose of supplying the excretion and feeding routes for any clinical cause. That is, it represents the formation of a surgically performed communication between the large intestine and the external environment through the abdominal wall through a mouth, the location, shape, type, contour and size depend on the cause of creation. Depending on their function, there are feeding ostomies such as gastrostomy and jejunostomy and there are excretion ostomies where ileostomies and colostomies are found (10). It is very possible that traumatic wounds, strangulated hernias or anorectal atresia are some of the reasons why ostomies were started as a therapeutic technique, offering at that time a minimal possibility of survival (11). On the other hand, the floating stoma is described as the protection of the wound bed with a bag that covers the intestinal surface fixed around the fistula and at the ends of the wound. Above this bag or protective plastic, an ostomy bag is fixed to collect the intestinal discharge, bringing with it proven benefits in tissue granulation (12). Subsequently, this idea has been perfected with the introduction of negative pressure therapy (TPN) in the management of large wounds (13). Which consists of a non-invasive wound healing system, which uses a localized negative pressure, (either continuously or intermittently) and controlled by a feedback system in the wound area in order to stimulate the healing of both acute and chronic wounds. This also has great advantages by reducing the bacterial load since it is a closed system, keeping the wound isolated and reducing the risk of external contamination; likewise, it does not require frequent dressing changes, which reduces handling and consequently the risk of infection. (14) There is evidence (although scarce) on the use of the floating stoma, which can mature at the Bogota exchange (BB) and which can shorten the surgical time while waiting for an improvement in the patient's condition to allow a "second look" with the possible definitive repair of the injury or implantation of the definitive stoma. The main indication

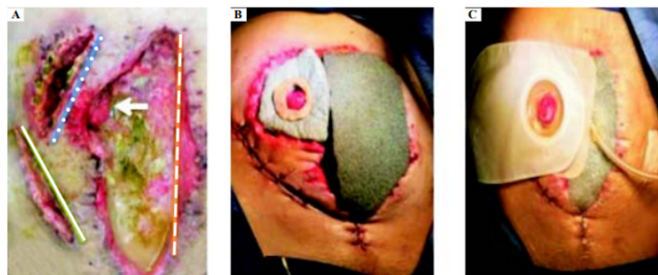## ASSISTED THERAPY WITH VACUUM AND FLOATING STOMA: A NEW WAY TO TREAT A PERI-STOMAL ABSCESS

for the use of BB and FS was abdominal sepsis due to secondary peritonitis due to rupture of hollow viscera (69.6%), EDC due to abdominal trauma (17.4%) and mesenteric ischemia (13.0%) (10). The stoma that is often required in these emergency situations is sometimes quite difficult to model due to mesenteric retraction, significant abdominal swelling, and / or intestinal distention (14). Vergara et al. They report a case report of a 58-year-old woman who was found to have acute Hinchey diverticulitis type III of the sigmoid colon, for which they performed a sigmoidectomy and Hartmann-type colostomy. On the sixth postoperative day, he was admitted for multiple intra-abdominal abscesses and peristomal abscess, so it was decided to perform a neopared with Viaflex® (Baxter Healthcare Corporation to fix the ostomy, everting its production on the new wall, limiting the drainage of fecal matter into the pockets periostomales, which is called “floating stoma” (Figure 2) (9).



**FIGURE 3:** Floating stoma. Neopared separating fecal production and peristomal space.

In the report by Ramirez et al. They indicate that the floating stoma is an alternative for the control of abdominal sepsis in the open abdomen with stomal retraction, in the case of a 39-year-old man with open appendectomy for acute appendicitis. Finding data of sepsis, open abdomen, retracted ileostomy and skin conditions. They performed surgical lavage, floating stoma, and placement of a vacuum-assisted closure system, with adequate results after placement, allowing control of sepsis and favoring early closure of the abdominal wall (Figure 3) (1).



**FIGURE 4:** A. Initial appearance of the abdomen. Mc Burney incision for appendectomy (solid line): stoma site (dotted line...). Wound in the midline supra and infraumbilical (intermittent line). Retracted stoma (arrow). B. Design of a floating stoma using a vacuum assisted closure system. C. Finished floating stoma.

Likewise, a 42-year-old man with a history of Crohn’s disease underwent an exploratory laparotomy with respect to an ileocecal mass, the following days he presented intestinal edema and frozen abdomen, so the bypass ostomy could not be performed. When performing the abdominal examination, they confirmed the frozen abdomen, with an inflamed, dilated and adherent intestine, for which they resorted to performing a resection of the anastomosis and leaving it in discontinuity, and DPR was started. Two large (19 French) drains were placed in the upper abdomen and a vacuum assisted closure (VAC) was placed in the abdomen. White VAC foam was placed for the wound to protect the intestine and covered with black foam for VAC therapy. On the third postoperative day for a new exploration, abdominal lavage and creation of a floating ileostomy, they noticed that the edema and intestinal inflammation were reduced again and the ostomy was viable (15). This confirms the benefit of the stoma in treating abdominal clinical complications. Therefore, the stoma is reserved mainly for those cases of late diagnosis (> 24 hours after DBE), extensive peritonitis with extensive contamination of the cavity, high comorbidity or general deterioration of the patient (sepsis or instability) (16). As in the case of peristomal pyoderma gangrenosum, which is a rare and incident variant in abdominal surgeries with 0.6% ostomies.

## 4 | DISCUSSION

In the present review of the literature, we found that vacuum-assisted therapy and the floating stoma represent an advance in the hospital environment because it reduces the mean time of hospitalization and the costs of the health system itself by bringing post-surgical benefits, according to the incidence overall number of ostomy and peristomal skin complications, estimated to be around 50%. The most commonly described are: retraction, hernias, prolapses, necrosis and alterations of the peristomal skin. In the early postoperative period, periosteal infections and abscesses are relatively rare, with a reported incidence between 2% and 14.8%. This is seen more frequently in revision ostomy surgeries, mainly due to preoperative colonization of the peristomal skin and bacterial inoculation in the perioperative period (17). In turn, among the complications of colostomies are periosteal suppurations, which are usually due to local suppuration, encompass parietal sepsis and laparotomy incision sepsis. They can occur during manipulation and colic exteriorization or during the performance of an ostomy during a septic intervention (18). Factors such as obesity, diabetes, malnutrition or chronic lung disease have been linked to complications of colostomies, such as stenosis, necrosis or peristomal abscess (19). Infection or abscess are infrequent complications, with an incidence that is between 2-14.8%. They are manifested by pain in the peristomal area, inflammation, suppuration and fever. They can be the result of infection from a hematoma or granuloma of the suture, or contamination of the surgical site when a stoma is revised or reconstructed in the same place. Infection and sepsis, if not detected in time, can evolve from peristomal inflammation, infection to the formation of an abscess; if it affects the entire circumference of the stoma, it may present dehiscence at the mucocutaneous junction (20). For this reason, the benefits of

Vacuum assisted therapy to treat peristomal abscess, being indicated for chronic open wounds such as pressure ulcers, venous insufficiency and diabetes ulcers, acute and traumatic wounds, subacute wounds such as dehiscent incisions or surgical site infection, partial thickness burns and flaps and grafts (21).

Negative pressure therapy (VAC) has been used in different types of infected wounds since according to studies the topical application of negative pressure to the wounds increases the elimination of exudates and accelerates the rate of new tissue formation since it improves tissue perfusion and the arrival of nutrients (22). The objective of which is to accelerate the granulation process of the bloody surface that results from an open abdomen, in association with parenteral and enteral nutritional assistance, as well as the use of other medications that tend to control and favor this process (23). As in the presentation of a case of management of paraostomal abscess in a patient with a history of laparotomy due to acute abdomen, so it was decided to use negative pressure therapy associated with a floating stoma, demonstrating its usefulness in this complex type of patient (3). For its part, the creation of a floating stoma refers to a stoma that will not be surrounded or fixed to the skin of the anterior abdominal wall, its use has been described in damage control surgeries and entero-atmospheric fistulas, as in the case of a patient with tertiary abdominal sepsis who was managed with a floating stoma (1). In the observational, analytical, retrospective and cross-sectional study that analyzed patients with intestinal ostomies who presented post-operative complications at the Abel Gilbert Pontón Hospital, a peristomal abscess was found among late complications in 66.67% (24).

## 5 | CONCLUSION

Vacuum assisted therapy and floating stoma can be used as an effective way to treat a peristomal abscess for all the positive characteristics that are triggered in its use as facilitating the drainage of the abscess from the cavity peritoneal in the most homogeneous way, thus correcting dead space and retraction, controlling sepsis without the need for general anesthesia or surgical intervention, avoids the perioperative risks, prolonged medical treatment, exhaustion and frustration of the medical team and the patient, even the use of these therapies promote a rapid closure of the abdominal wall, however, despite being a viable option, should carry out more study to allow more comprehensive verification of

## ASSISTED THERAPY WITH VACUUM AND FLOATING STOMA: A NEW WAY TO TREAT A PERIOSTOMAL ABSCESS

the use of these techniques in specific pathologies such as a population with the presence of peristomal abscess.

### REFERENCES

1. Ramírez-Ramírez M, Marino. Estoma flotante: Alternativa para el control de sepsis abdominal en abdomen abierto con retracción estomal. *Rev Mex de Cirugía del Aparato Digestivo*. 2018;p. 94–96.
2. Velasco M, M, Escovar J, F, Calvo P, A. Estado actual de la prevención y tratamiento de las complicaciones de los estomas. *Cir Esp*. 2014;92:149–56.
3. Vergara A. Terapia asistida con vacío y estoma flotante (floating stoma). *Revista de cirugía*. 2021;73:503–508.
4. Boza A, Senent V, Durán FPM, Ciuró. TEMA 16: ABDOMEN ABIERTO INDICACIONES Y COMPLICACIONES ASOCIADAS;p. 247–247.
5. Díaz JJ, Dutton WD, Ott MM, Cullinane DC, Alouidor R, Armen SB. Eastern Association for the Surgery of Trauma: a review of the management of the open abdomen-part 2 “Management of the open abdomen. *J Trauma*. 2011;71:502–514.
6. Layton B, Dubose J, Nichols S, Connaughton J, Jones T, Pratt J. Pacifying the open abdomen with concomitant intestinal fistula: a novel approach. *Am J Surg*. 2010;199:48–50.
7. Riquoir C, Grasset E, Bellolio F. Absceso peristomal secundario a perforación intestinal por cuerpo extraño: presentación de un caso. *Revista de cirugía*. 2021;73:203–207.
8. Ugwu AU, Kerins N, Malik M. Traumatic small bowel perforation in a case of a perineal hernia. *J Surg Case Reports*. 2018;2018:1–3.
9. Gomez, Arturo Vergara, et al. ”TERAPIA ASISTIDA CON VACÍO Y ESTOMA FLOTANTE (FLOATING STOMA). UNA NUEVA FORMA DE TRATAR UN ABSCESO PERIOSTOMAL.” *Revista de Cirugía* 73.4 (2020).;.
10. Manterola C. Floating stoma: An alternative strategy in the context of damage control surgery. *J Visceral Surg*. 2016;153:419–443.
11. García, del Carmen Vázquez M, , Prats TP, editores. *Manual de cuidados en ostomías*. Difusión Avances de Enfermería (DAE); 2015.
12. Eguía P, Andrés. Diseño y desarrollo de una metodología de estandarización para prótesis personalizadas en el control local del efluvio intestinal por fistula enteroatmosférica. 2020;.
13. Muñoz-Cruzado, Durán V. Actualización sobre el manejo de la fistula enterocutánea y fistula enteroatmosférica;.
14. Malgras B, Barbier O, Pasquier P. Floating stoma and abdominal negative-pressure therapy. *Journal of visceral surgery*. 2017;154:310–310.
15. Mcguirk M, Kajmolli A, Gachabayov M, Haider A, Bronstein M, Spatz D, et al. Use of Direct Peritoneal Resuscitation for Intra-Abdominal Catastrophes: A Technical Note. *Surg Technol Int*. 2020;37:33245138–33245138.
16. Boza A, Senent V, Durán FPM, Ciuró. TEMA 16: ABDOMEN ABIERTO INDICACIONES Y COMPLICACIONES ASOCIADAS;p. 247–247.
17. Riquoir C, Grasset E, Bellolio F. Absceso peristomal secundario a perforación intestinal por cuerpo extraño: presentación de un caso. *Revista de cirugía*. 2021;73:203–207.
18. Thibaudeau E. Tratamiento quirúrgico de las complicaciones de las colostomías. *EMC-Técnicas Quirúrgicas-Aparato Digestivo*. 2013;29:1–15.
19. Tadeo-Ruiz G. Eventración paraestomal: antecedentes, estado actual y expectativas de futuro. *Cirugía Española*. 2010;87:339–349.

20. Estrella R, Katherine J. Factores que inciden en las complicaciones de los pacientes ileostomizados en el Hospital Dr. 2015;.
21. Montes EI, Flores. Intervenciones de enfermería en el manejo avanzado de heridas a través de terapia asistida por vacío. Revista mexicana de enfermería cardiológica. 2008;16:24–27.
22. Layos, Pilar López. "TERAPIA ASISTIDA POR VACIO EN CIRUGIA ONCOLOGICA MAMARIA.";
23. Rojas C, Manuel E. Uso de La Terapia VAC®(Cicatrización Asistida Por Vacío) en el manejo de las fistulas enterostómicas en el Hospital Universitario De La Samaritana durante los años 2010 A 2014. 2015;.
24. Área De Emergencia Zuñiga FMAFAACEP-COIE, 2019 EHAGA, Pontón. REVISTA ABDOMEN AGUDO. 2019;1:13–18.

**How to cite this article:** Duarte Pérez A., D.M.V., L.C.G.M., R.A.O.B., J.D.S.R., O.I.A.S., J.J.M.A., M.F.R.R. **Assisted Therapy with Vacuum and Floating Stoma: A New Way to Treat a Peristomal Abscess.** Journal of Medical Research and Health Sciences. 2021; 1629–1635. <https://doi.org/10.52845/JMRHS/2021-4-12-4>