



Combined effect of low dose atorvastatin, aspirin, clopidogrel and cessation of smoking for one year on totally occluded left anterior descending coronary artery in 39-year-old obese physician: a case report

Khin Phyu Pyar^{1*}, Chan Aye Aung³, Aung Si Myo⁴, Ye Myat Htun², Thant Zaw Maung⁴, Soe Win Hlaing³, Zar Ni Htet Aung³, Nyan Lin Maung³, Aung Phyo Kyaw³, Min Lynn Zaw Oo³, Sai Kyaw Tay Zar⁴, Nay Myo Aung⁴, Phyo Htet Oo⁴, Si Thu Zaw Win⁴, Nay Aung Win⁴, Aung Ko Oo⁴

¹Professor and Head/Senior Consultant Physician, Department of Medicine/ Department of Nephrology, Defence Services Medical Academy, No. (1) Defence Services General Hospital (1000-Bedded)

²Professor/Senior Consultant Physician, Department of Medicine, Defence Services Medical Academy

³Consultant Physician, No. (1) Defence Services General Hospital (1000-Bedded)

⁴Consultant Cardiologist, No. (1) Defence Services General Hospital (1000-Bedded)



Corresponding author: **Khin Phyu Pyar**

Case summary

A 39-year-old physician had severe central chest pain and cardiogenic shock due to acute inferior myocardial infarction one year ago; bare metal stent was inserted into occluded right coronary artery, culprit artery. Left anterior descending artery (LAD) was found to be totally occluded too, planned for future procedure. He had multiple risk factors: high BMI 28, heavy smoking, high cholesterol 220 mg% and sedentary life style. He quit smoking after the event. He has been taking atorvastatin 10 mg, aspirin 75 mg and clopidogrel 75 mg in addition to diuretics and low dose ramipril. He could not do exercise as his effort tolerance was poor.

One year later, recheck coronary angiogram revealed a good flow in right coronary artery; moreover, there was distal flow in totally occluded LAD. Therefore, bare metal stent was inserted after dilatation. Blood tests were almost the same.

In this patient, spontaneous flow in totally occluded LAD was due to combined effect of low dose atorvastatin, aspirin, clopidogrel and cessation of smoking for one year; not due to exercise or weight reduction. Low dose statin and smoking cessation had effect on atheromatous plaque on LAD.

Key words: combined effect, low dose atorvastatin, aspirin, clopidogrel, smoking, totally occluded left anterior descending coronary artery, obese

Copyright : © 2021 The Authors. Published by Medical Editor and Educational Research Publishers Ltd. This is an open access article under the CC BY-NC-ND license (<https://creativecommons.org/licenses/by-nc-nd/4.0/>).

Combined effect of low dose atorvastatin, aspirin, clopidogrel and cessation of smoking for one year on totally occluded left anterior descending coronary artery in 39-year-old obese physician: a case report

Introduction

IHD is one of non-communicable diseases with significant mortality and morbidity; the prevalence is rising not only in developed countries but also in developing countries. Some risk factors are modifiable like hypercholesterolemia, hypertension, diabetes, smoking; however, some are not like old age, sex and family history.

Statins play an important role in both primary and secondary prevention of CAD (Ostadal, 2012); it has anti-inflammatory action on heart (Koushki et al., 2021), anti-plaque activity in addition to cholesterol lowering effect. Primary prevention of CAD is important; and, statins seemed to be beneficial for the primary prevention of CHDs but have no effect on CHD death and all-cause mortality (Li et al., 2019). Regarding secondary prevention, some are short term survey (Toso et al., 2017); and, some are long term (Kim et al., 2018). Although high intensity statins with high dose are recommended in both stable CAD and acute coronary syndrome (ACS), statin prescription pattern was varied among physicians (Brophy & Costa, 2006); it was named as statin wars.

The choice of statin and dosage of statin had controversies in stable CAD; one results showed that effect of high-dose versus usual-dose statin therapy in individual coronary artery disease patients enables selection of high-risk patients that benefit most from more aggressive therapy (Dorresteijn et al., 2013). Moreover, one study compared with moderate statin therapy, intensive statin therapy reduces all-cause mortality in patients with recent ACS but not in patients with stable CHD (Afilalo et al., 2007). Compared with moderate statin therapy, intensive statin therapy reduces all-cause mortality in patients with recent ACS but not in patients with stable CHD (Afilalo et al., 2007).

However, all cause of mortality must be consider in treating patients; Danchin & Simon. (2020) pointed out that the fact “high-intensity LLT decreased potentially lethal CV events [acute myocardial infarction (AMI) and stroke] in stable CAD, it did not reduce mortality, compared with conventional-dose statins (Danchin & Simon, 2020). Statin therapy after revascularization procedure reduced MACE major atherosclerotic cerebrovascular and cardiovascular events (Yong

et al., 2022). Therefore, one reviewer highlighted the need for the optimal timing, dosage, and type of statin therapy as well as the problems associated with adverse effects (Lim, 2013). However, personalized therapy was the best (Muniyappa et al., 2018).

Smoking was found to be related to CAD severity (Salehi et al., 2021); and, cigarette smoking has 2 fold increase risks of CAD (Oshunbade et al., 2021). Several population study proved the association between smoking and prevalence of CAD (Basnet et al., 2019). There was still impact on mortality of continuing to smoke one year after the angiographic diagnosis of coronary artery disease; it was reported in one prospective cohort study(Hammal et al., 2014). One report on smoking, CAD and ecNOS4a allele, smoking-dependent excess coronary risk was found in those having excess of homozygotes for the rare ecNOS4a allele. It predisposed to endothelial dysfunction (Wang et al., 1996).

Case presentation

One year ago, a 39-year-old physician with BMI 28 had severe central chest pain and cardiogenic shock due to acute inferior myocardial infarction as evidenced by ST elevation in inferior leads; and, bare metal stent was inserted into occluded right coronary artery, culprit artery. Figure (1)(a) shows ECG at presentation and (b) after stenting.

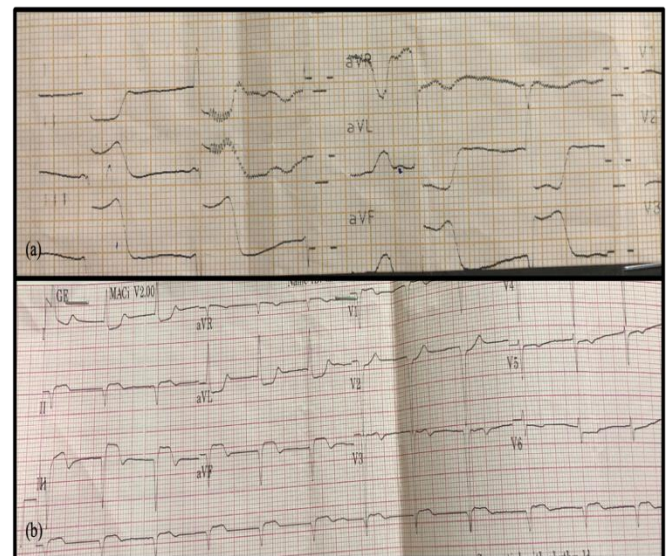


Figure (1) (a) ECG on arrival when he had cardiogenic shock and chest pain, showing ST elevation in inferior leads and (b) after Primary PCI to occluded right coronary artery (one year ago)

Combined effect of low dose atorvastatin, aspirin, clopidogrel and cessation of smoking for one year on totally occluded left anterior descending coronary artery in 39-year-old obese physician: a case report

Figure (2)(a) reveals occlusion at right coronary artery before and (b) after coronary angioplasty and stent.

Left anterior descending artery (LAD) was totally occluded too.

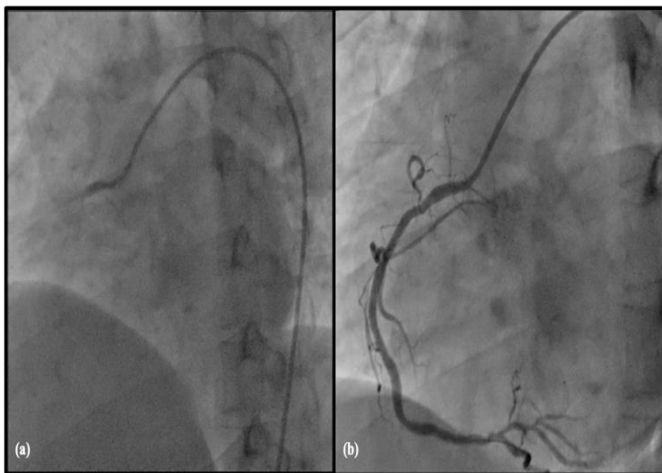


Figure (2) (a) Complete occlusion of right coronary artery and (b) after stent to occlusion of right coronary artery (LAO view) (one year ago)

It is clearly seen in Figure (3). It seemed to be chronic occlusion as ECG findings pointed to right coronary artery; thus, occlusion in LAD was planned for further procedure.

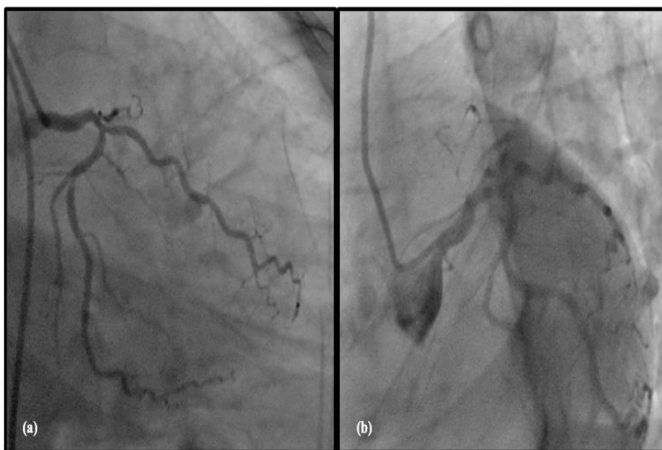

Figure (3) (a) and (b) Complete occlusion of LAD coronary artery (LAO caudal view) (one year ago)

Staged percutaneous intervention (while in hospital or after discharge) of a significantly stenosed nonculprit artery in patients presenting with an ST-segment–elevation myocardial infarction is recommended in select patients to improve outcomes.

Although his age is under 40, he had multiple risk factors: high BMI 28, heavy smoking, high cholesterol 220 mg% and sedentary life style. He

quit smoking after the event. He has been taking atorvastatin 10 mg, aspirin 75 mg and clopidogrel 75 mg in addition to diuretics and low dose ramipril. He could not do exercise as his effort tolerance was poor; also, walking outdoor due to COVID-19 pandemic situation.

One year later, his effort tolerance was the same; no chest pain. His BMI was the same. His life style was still sedentary. No significant changes in ECG, chest radiograph and echocardiogram were seen. Recheck coronary angiogram one year apart revealed good flow in right coronary artery; moreover, there was distal flow in previously occluded LAD. Figure (4) illustrate it. Wiring was done.

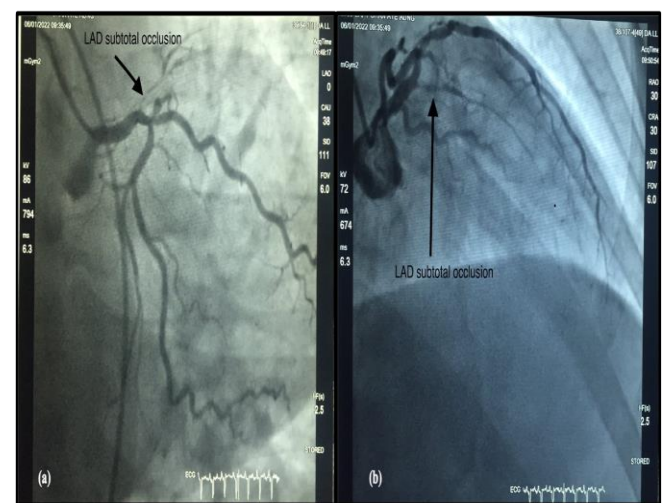


Figure (4) Coronary angiogram in 2022 showing narrowing at ostio-proximal LAD (a) (AP caudal view) and (b) (RAO 30 CRA 30 view) i.e., small tract

Figure (5) (a) demonstrates it. Therefore, drug eluting stent was inserted after dilatation; it can be seen in Figure (5)(b).

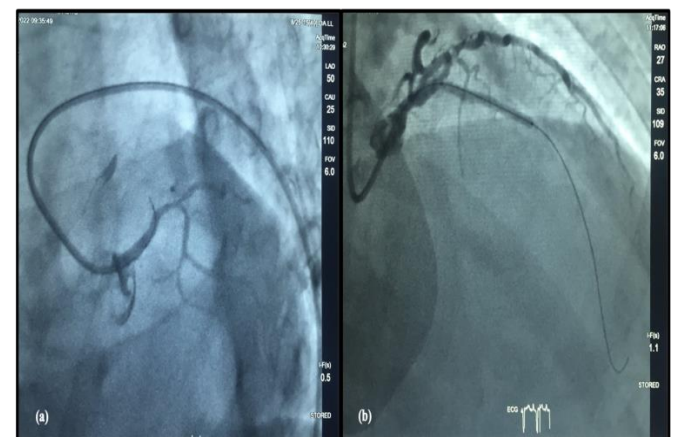


Figure (5) (a) Wiring to LAD (LAO 50 Caudal 25 view) and (b) stent implantation with DES to LAD (RAO Cranial view)

Combined effect of low dose atorvastatin, aspirin, clopidogrel and cessation of smoking for one year on totally occluded left anterior descending coronary artery in 39-year-old obese physician: a case report

Figure (6) reveals excellent flow after stent. The procedure was uneventful.

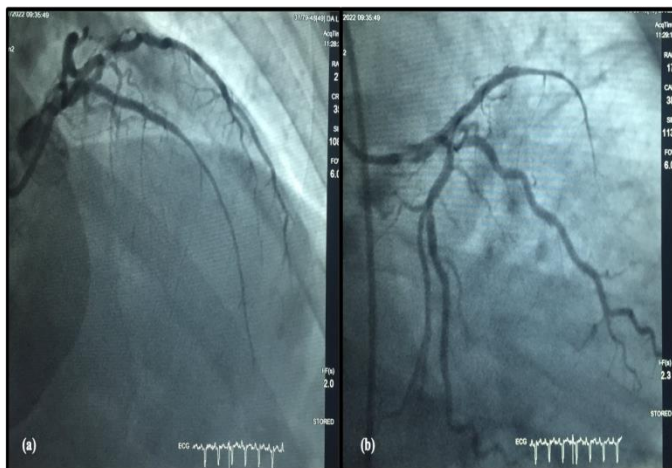


Figure (6) After stenting to LAD in RAO (a) Cranial view and (b) Caudal view

Blood tests were almost the same: hemoglobin 14.5 gm%, PCV 45; cholesterol 210 mg%; triglycerides 150 mg%; uric acid 6.9 mg%; and serum creatinine 100 $\mu\text{mol/L}$. His effort tolerance was better after stenting; and, he was on anti-failure treatment, anti-platelets and atorvastatin 10 mg daily.

In this patient, spontaneous flow in totally occluded LAD was due to combined effect of low dose atorvastatin, aspirin, clopidogrel and cessation of smoking for one year; not due to exercise or weight reduction. He does not have family history of ischemic heart disease or dyslipidemia.

Several reports mentioned longitudinal studies on anti-lipid drugs particularly statins. The recommended dose was high dose statin having high intensity in those with normal kidney function. This patient has been taking low dose atorvastatin (10 mg/ day) though cardiologists advised to take high dose. Low dose statin had effect on atheromatous plaque on LAD. We need large scale study with low dose statin in Myanmar population with atheromatous arterial diseases.

Discussion

In first event, he was planned for staged percutaneous intervention (while in hospital or after discharge) of a significantly stenosed nonculprit artery in patients presenting with an ST-segment– elevation myocardial infarction is recommended in select patients to improve outcomes. Percutaneous intervention of the nonculprit artery at the time of primary

percutaneous coronary intervention is less clear and may be considered in stable patients with uncomplicated revascularization of the culprit artery, low-complexity nonculprit artery disease, and normal renal function. In contrast, percutaneous intervention of the non-culprit artery can be harmful in patients in cardiogenic shock (Lawton et al., 2022). The decision was correct; as we do not have micro instruments for LAD, we rely on conservative measures.

In this patient, spontaneous flow in totally occluded LAD was due to combined effect of low dose atorvastatin, aspirin, clopidogrel and cessation of smoking for one year; not due to exercise or weight reduction. He does not have family history of ischemic heart disease or dyslipidemia. Several reports mentioned longitudinal studies on anti-lipid drugs particularly statins. The recommended dose was high dose statin having high intensity with normal kidney function. The patient has been taking low dose atorvastatin (10 mg/ day) though cardiologists advised high dose; personnel choice. Therefore, even low dose statin had effect on atheromatous plaque on previously totally occluded LAD. It may be due to regression of the atherosclerotic lesions which can occur after lipid lowering, without change in vessel wall thickness or vessel wall area; anti-inflammatory action of statin (Koushki et al., 2021), plaque stability, plaque regression, reduction in inflammation and oxidative stress was reported in patients with mild to moderate coronary artery stenosis (Mahajan & Chandra, 2020). The dose of atorvastatin (10 mg/ day) was one fourth of recommended dose for secondary prevention; and, it even maintained the patency of previous stent as well as reopening of previously totally occluded LAD together with two anti-platelets and smoking cessation.

Another explanation was “personalized therapy in statin” which was mentioned by some report (Muniyappa et al., 2018). We need large scale study with low dose atorvastatin in Myanmar population with stable coronary artery disease.

Regarding anti-platelets therapy, two drugs (aspirin and clopidogrel) are recommended for at least one year following stent; also, they had effect on LAD.

In this patient, prevention of further progression of atherosclerosis in LAD and recanalization of totally occluded LAD were mainly due to

Combined effect of low dose atorvastatin, aspirin, clopidogrel and cessation of smoking for one year on totally occluded left anterior descending coronary artery in 39-year-old obese physician: a case report

cessation of smoking. It also proved the importance of previously known fact “smoking and coronary artery disease”. Cigarette smoking is related to thrombogenesis, atherogenesis, and platelet function; thus, it creates prothrombotic state (Inoue, 2004). Moreover, platelet aggregation, vasomotor reactivity, and direct myocardial effects may also be provoked by smoking. Therefore, smoking is clearly related to an increased risk of acute myocardial infarction and sudden death. The overwhelming evidence that the cardiovascular risk is substantially reduced among quitters. Such risk reduction becomes apparent quite rapidly upon quitting (within one to three years) and continues to decline over the next five to ten years, although it may not reach the non-smokers' level in some heavy smokers. This patient quit smoking rapidly; thus, prothrombotic state improved over one year with the additive effect of atorvastatin and antiplatelets. If we got a chance, the patient should be screened for polymorphism *ecNOS4a/b*. The patient may be smoking-dependent excess coronary risk in excess of homozygotes for the rare *ecNOS4a* allele; it is consistent with predisposition to endothelial dysfunction (Wang et al., 1996).

Conclusion

Combined effect of low dose atorvastatin 10 mg per day, aspirin, clopidogrel and cessation of smoking for one year caused reopening of previously totally occluded left anterior descending coronary artery as well as patency of previous bare metal stent in right coronary artery in 39-year-old obese physician. The patient may have excess of homozygotes for the rare *ecNOS4a* allele, smoking-dependent excess coronary risk gene polymorphism. Or, two anti-platelets have additive effect on low dose atorvastatin.

Recommendation

We need large scale study with low dose statin in Myanmar population with stable coronary artery disease.

Acknowledgements

The authors would like to thank the patient for giving consent to this article. Also, to all doctors and nursing team for making great efforts in caring him. The authors acknowledged the following team; cardiac medical team – Dr Aung Si Myo, intensive care team - Prof Yu Aye Latt,

administrative support - Prof Ko Ko Lwin, Prof Kyaw Zay Ya, and Prof Myint Zaw.

Declaration of conflict of interest

The authors declared no potential conflicts of interests with respect to authorship and publication of this article.

Ethical approval

Our institution does not require ethical approval for reporting cases.

Funding

The authors received no financial support for publication of this article.

Informed consent

The informed consent for publication in this article was obtained from patient.

References

1. Afilalo, J., Majdan, A. A., & Eisenberg, M. J. (2007). Intensive statin therapy in acute coronary syndromes and stable coronary heart disease: A comparative meta-analysis of randomised controlled trials. *Heart*, 93(8), 914. <https://doi.org/10.1136/hrt.2006.112508>
2. Basnet, T. B., Xu, C., Mallah, M. A., Indayati, W., Shi, C., Xu, J., & Gu, A. (2019). Association of smoking with coronary artery disease in Nepalese populations: A case control study. *Toxicology Research*, 8(5), 677–685. <https://doi.org/10.1039/C9TX00083F>
3. Brophy, J. M., & Costa, V. (2006). Statin wars following coronary revascularization – Evidence-based clinical practice? *Canadian Journal of Cardiology*, 22(1), 54–58. [https://doi.org/10.1016/S0828-282X\(06\)70239-2](https://doi.org/10.1016/S0828-282X(06)70239-2)
4. Danchin, N., & Simon, T. (2020). High-intensity lipid-lowering regimens in patients with stable coronary artery disease: The intriguing question of all-cause mortality. *European Heart Journal - Cardiovascular Pharmacotherapy*, 6(5), 328–330. <https://doi.org/10.1093/ehjcvp/pvz049>
5. Dorresteijn, J. A. N., Boekholdt, S. M., van der Graaf, Y., Kastelein, J. J. P., LaRosa, J. C., Pedersen, T. R., DeMicco, D. A., Ridker, P. M., Cook, N. R., & Visseren, F. L. J. (2013). High-Dose Statin Therapy in Patients With Stable Coronary Artery Disease. *Circulation*, 127(25), 2485–2493. <https://doi.org/10.1161/CIRCULATIONAHA.112.000712>

Combined effect of low dose atorvastatin, aspirin, clopidogrel and cessation of smoking for one year on totally occluded left anterior descending coronary artery in 39-year-old obese physician: a case report

6. Hammal, F., Ezekowitz, J. A., Norris, C. M., Wild, T. C., Finegan, B. A., & for the APPROACH Investigators. (2014). Smoking status and survival: Impact on mortality of continuing to smoke one year after the angiographic diagnosis of coronary artery disease, a prospective cohort study. *BMC Cardiovascular Disorders*, 14(1), 133. <https://doi.org/10.1186/1471-2261-14-133>
7. Inoue, T. (2004). Cigarette Smoking as a Risk Factor of Coronary Artery Disease and its Effects on Platelet Function. *Tobacco Induced Diseases*, 2(1), 2–2. PMC. <https://doi.org/10.1186/1617-9625-2-2>
8. Kim, B. S., Yang, J. H., Jang, W. J., Song, Y. B., Hahn, J.-Y., Choi, J.-H., Choi, K. H., Kim, S.-H., Chun, W. J., Gwon, H.-C., & Choi, S.-H. (2018). Long-term Survival Benefit of Statin in Patients with Coronary Chronic Total Occlusion without Revascularization. *J Korean Med Sci*, 33(18). <https://doi.org/10.3346/jkms.2018.33.e134>
9. Koushki, K., Shahbaz, S. K., Mashayekhi, K., Sadeghi, M., Zayeri, Z. D., Taba, M. Y., Banach, M., Al-Rasadi, K., Johnston, T. P., & Sahebkar, A. (2021). Anti-inflammatory Action of Statins in Cardiovascular Disease: The Role of Inflammasome and Toll-Like Receptor Pathways. *Clinical Reviews in Allergy & Immunology*, 60(2), 175–199. <https://doi.org/10.1007/s12016-020-08791-9>
10. Lawton, J. S., Tamis-Holland, J. E., Bangalore, S., Bates, E. R., Beckie, T. M., Bischoff, J. M., Bittl, J. A., Cohen, M. G., DiMaio, J. M., Don, C. W., Fremes, S. E., Gaudino, M. F., Goldberger, Z. D., Grant, M. C., Jaswal, J. B., Kurlansky, P. A., Mehran, R., Metkus, T. S., Nwacheta, L. C., ... Zwischenberger, B. A. (2022). 2021 ACC/AHA/SCAI Guideline for Coronary Artery Revascularization: A Report of the American College of Cardiology/American Heart Association Joint Committee on Clinical Practice Guidelines. *Journal of the American College of Cardiology*, 79(2), e21–e129. <https://doi.org/10.1016/j.jacc.2021.09.006>
11. Li, M., Wang, X., Li, X., Chen, H., Hu, Y., Zhang, X., Tang, X., Miao, Y., Tian, G., & Shang, H. (2019). Statins for the Primary Prevention of Coronary Heart Disease. *BioMed Research International*, 2019, 4870350. <https://doi.org/10.1155/2019/4870350>
12. Lim, S. Y. (2013). Role of statins in coronary artery disease. *Chonnam Medical Journal*, 49(1), 1–6. PubMed. <https://doi.org/10.4068/cmj.2013.49.1.1>
13. Mahajan, K., & Chandra, K. S. (2020). Current Concepts in Management of Lipid Abnormalities in Patients With Coronary Artery Disease. *Indian Journal of Clinical Cardiology*, 1(3–4), 164–173. <https://doi.org/10.1177/2632463620943020>
14. Muniyappa, R., Noureldin, R. A., Abdelmoniem, K. Z., El Khouli, R. H., Matta, J. R., Hamimi, A., Ranganath, S., Hadigan, C., Nieman, L. K., & Gharib, A. M. (2018). Personalized Statin Therapy and Coronary Atherosclerotic Plaque Burden in Asymptomatic Low / Intermediate-Risk Individuals. *Cardiorenal Medicine*, 8(2), 140–150. <https://doi.org/10.1159/000487205>
15. Oshunbade, A. A., Kassahun-Yimer, W., Valle, K. A., Hamid, A., Kipchumba, R. K., Kamimura, D., Clark, D., White, W. B., DeFilippis, A. P., Blaha, M. J., Benjamin, E. J., O'Brien, E. C., Mentz, R. J., Rodriguez, C. J., Fox, E. R., Butler, J., Keith, R. J., Bhatnagar, A., Marie Robertson, R., ... Hall, M. E. (2021). Cigarette Smoking, Incident Coronary Heart Disease, and Coronary Artery Calcification in Black Adults: The Jackson Heart Study. *Journal of the American Heart Association*, 10(7), e017320. <https://doi.org/10.1161/JAHA.120.017320>
16. Ostadal, P. (2012). Statins as first-line therapy for acute coronary syndrome? *Experimental and Clinical Cardiology*, 17(4), 227–236. PubMed.
17. Salehi, N., Janjani, P., Tadbiri, H., Rozbahani, M., & Jalilian, M. (2021). Effect of cigarette smoking on coronary arteries and pattern and severity of coronary artery disease: A review. *The Journal of International Medical Research*, 49(12), 3000605211059893–3000605211059893. PubMed. <https://doi.org/10.1177/03000605211059893>
18. Toso, A., De Servi, S., Leoncini, M., Angiolillo, D. J., Calabrò, P., Piscione, F., Cattaneo, M., Maffeo, D., Bartorelli, A., Palmieri, C., De Carlo, M., Capodanno, D., Genereux, P., Bellandi, F., Barozzi, C., Tomasi, L., Della Riva, D., & Palmerini, T. (2017). Effects of statin therapy on platelet reactivity after percutaneous coronary revascularization in patients with acute

Combined effect of low dose atorvastatin, aspirin, clopidogrel and cessation of smoking for one year on totally occluded left anterior descending coronary artery in 39-year-old obese physician: a case report

coronary syndrome. *Journal of Thrombosis and Thrombolysis*, 44(3), 355–361.

<https://doi.org/10.1007/s11239-017-1541-x>

19. Wang, X. L., Sim, A. S., Badenhop, R. F., McCreddie, R. M., & Wilcken, D. E. L. (1996). A smoking-dependent risk of coronary artery disease associated with a polymorphism of the endothelial nitric oxide synthase gene. *Nature Medicine*, 2(1), 41–45. <https://doi.org/10.1038/nm0196-41>
20. Yong, J., Tian, J., Zhao, X., Yang, X., Zhang, M., Zhou, Y., He, Y., & Song, X. (2022). Revascularization or medical therapy for stable coronary artery disease patients with different degrees of ischemia: A systematic review and meta-analysis of the role of myocardial perfusion. *Therapeutic Advances in Chronic Disease*, 13, 20406223211056710. <https://doi.org/10.1177/20406223211056713>

How to cite this article: K. P. Pyar, et.al .. Combined effect of low dose atorvastatin, aspirin, clopidogrel and cessation of smoking for one year on totally occluded left anterior descending coronary artery in 39-year-old obese physician: a case report. *Journal of Medical Research and Health Sciences*. 2022 ;5(3)1825–1831.<https://doi.org/10.52845/JMRHS/2022-5-4>