




Research Article

Open Access Journal



## Bogotá Bag as a Conservative Measure for Open Abdomen Secondary to Intra-Abdominal Sepsis

Diego Alejandro Largo Cordoba<sup>1\*</sup> , Sandra Marcela Figueroa Cardenas<sup>2</sup>, Oscar Oswaldo López Bravo<sup>3</sup>, Camila Andrea Torres Castro<sup>4</sup>, Jorge Julian Mendoza Anguila<sup>5</sup>, Juan Pablo Montoya Castro<sup>6</sup>, Christian Orlando Pabon Valenzuela<sup>7</sup>, Juan Felipe Casabon Pastrana<sup>8</sup>

Corresponding Author: Diego Alejandro Largo Cordoba

<sup>1</sup>General Physician, Universidad de Antioquia

<sup>2</sup>General Physician, Universidad del Magdalena

<sup>3</sup>General Physician, Universidad Nacional de Colombia

<sup>4</sup>General Physician, Universidad Metropolitana de Barranquilla

<sup>5</sup>General Physician, Universidad Cooperativa de Colombia, sede Santa Marta

<sup>6</sup>General Physician, Universidad Cooperativa de Colombia

<sup>7</sup>General Physician, Universidad de Caldas

<sup>8</sup>Medical Student, Universidad El Bosque

### Abstract:

Sepsis is defined as the inflammation of the serous membrane that delimits the abdominal cavity and the organs contained in it. In the treatment of patients with intra-abdominal sepsis, and due to the high morbidity and mortality that it entails, modifications have been introduced in order to find the most appropriate treatment to obtain better results. This is where the open abdomen plus Bogotá bag technique emerges. The open abdomen technique is a very important surgical method and today it is still fully valid, having very precise indications in abdominal sepsis, in severe trauma and in some other pathologies, however, it is true that scenarios may arise where this technique can compromise therefore, the use of additional and conservative measures has been seen as necessary to help increase the survival rate of patients, this is where the "Bogota Bag" arises, which consists of fixing to the fascia or the skin of a 3L sterile irrigation bag or similar material, which provides atraumatic coverage of the exposed viscera and allows permanent visualization and monitoring of their status. It is a fact that this last procedure has positively promoted the preservation of the open abdomen secondary to intra-abdominal sepsis and has brought with it multiple advantages and utilities that will be described throughout this bibliographical review.

**Key Words:** Sepsis, open abdomen, Bogotá pouch, preservation, intra-abdominal

**Copyright :** © 2021 The Authors. Published by Medical Editor and Educational Research Publishers Ltd. This is an open access article under the CC BY-NC-ND license (<https://creativecommons.org/licenses/by-nc-nd/4.0/>).



### Introduction

Intra-abdominal sepsis is defined as the result of the host's systemic response to a microorganism, this pathology consists of the invasion of the body, initially located in the abdominal organs, by pathogenic microorganisms

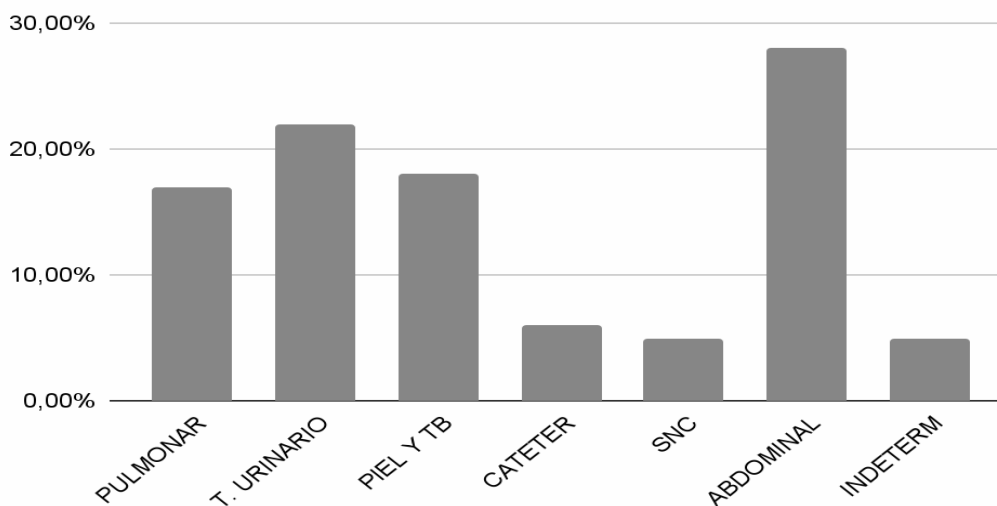
such as bacteria, viruses, fungi and parasites, where the body promotes the reaction that these and their toxins cause, causing damage to tissues and organs (1,2). Other authors define it as the inflammation of the serous membrane that delimits the abdominal cavity and the organs

## Bogotá Bag as a Conservative Measure for Open Abdomen Secondary to Intra-Abdominal Sepsis

contained in it, it is even considered one of the main causes of death in patients with abdominal trauma due to the perforation or rupture of intestinal loops or stomach, it induces the dissemination in the peritoneal cavity of poorly digested food or feces, with the consequent danger

of sepsis, in addition, vascularization disorders of an intestinal loop due to contusion of the intestinal wall or its meso may manifest late as necrosis parietal punctate and peritoneal contamination which would cause sepsis, septic shock, multiple organ dysfunction and death (3,4).

**Figure 1. Infectious foci related to sepsis.**

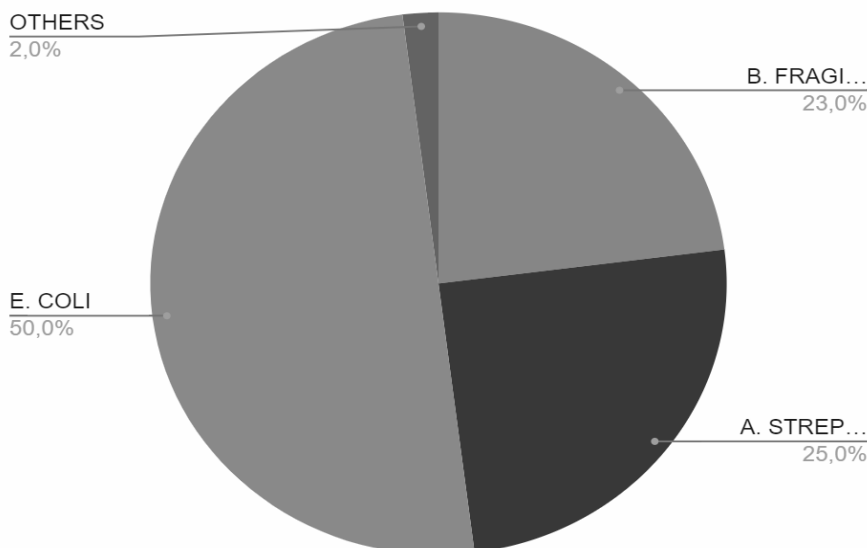


### Taken from Yolima Pertuz-Meza et al. Epidemiological aspects of sepsis in patients in intensive care- santa marta

Sepsis continues to be common, affects 12-34% of patients admitted to the ICU (Intensive Care Unit), and is undoubtedly a life-threatening complication of an infection. This condition can have multiple sources of infection such as the lungs, the skin, the CNS. However, it is abdominal sepsis that generally presents more frequently, according to studies by Yolima Pertuz et al. In a population of

patients in intensive care in Cartagena, abdominal sepsis encompasses around 28% of cases, as shown in Figure 1 (5,6). Any microorganism can lead to septic symptoms, but it is more frequently Bacteria have been described, in fact, bacterial infections are the most common triggers, Escherichia coli has generally been described as the main trigger, among others observed in figure 2, for this reason, its early recognition is crucial to treat patients before that their condition worsens and is fatal (7).

**Figure 2. Most frequent microorganisms capable of causing intra-abdominal sepsis.**

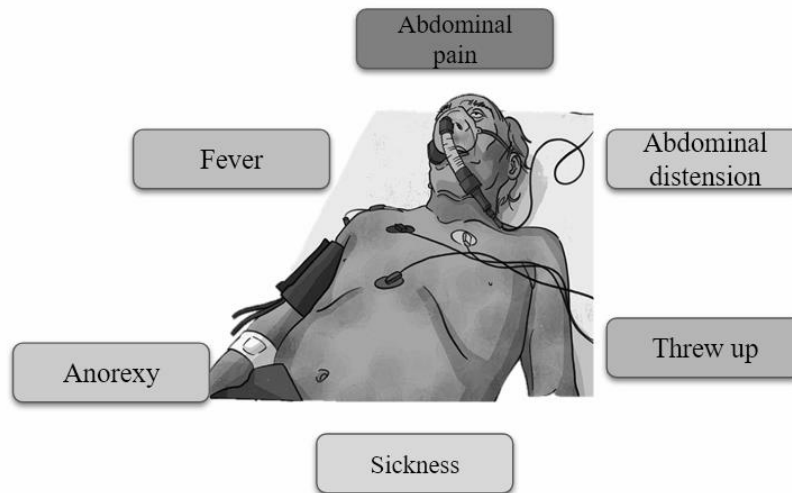


### Bogotá Bag as a Conservative Measure for Open Abdomen Secondary to Intra-Abdominal Sepsis

Sepsis is usually caused by poor asepsis and antisepsis habits and its symptoms, with the exception of immunosuppressed individuals, patients usually present frank data of the systemic inflammatory response syndrome, however, the

symptoms may vary depending on the affected abdominal area. . Abdominal pain is the most frequent symptom, followed by fever among others that can be seen in Figure 3 (8).

**Figure 3. Clinical manifestations present in patients with intra-abdominal sepsis.**



However, intra-abdominal sepsis may give rise to the need to resort to the open abdomen technique. In fact, it is a surgical strategy that has resulted from advances in the operative management of patients with complicated intra-abdominal infection and has recently been used in patients with abdominal trauma. serious. However, even with the risks that can be run in certain scenarios, currently one of the strategies for the management of these patients with intra-abdominal sepsis most often involves the use of the open abdomen technique such as planned relaparotomy or repair. abdominal surgery in stages, which consists of performing daily washings of the peritoneal cavity until it is sterilized, leaving the abdominal organs covered by a prosthesis, and relaparotomy on demand, which involves performing a first procedure, trying to close the wall abdominal if possible, and evaluating clinically for future re-explorations and thanks to the ease of being able to eliminate the source of infection, remove pus and intra-abdominal debris that these techniques allow, mortality from sepsis compared to years ago was even 50% lower, However, it is clear that following abdominal opening to control and eliminate sepsis can e Although there are certain complications such as reinfections that can compromise the patient's life, it also creates numerous risks of high morbidity for patients, such as hydroelectrolytic alterations,

contamination of abdominal organs, development of enteroatmospheric fistulas, obstructive adhesions and giant hernia defects of the abdominal wall with important aesthetic and functional consequences (9). To solve this problem and look for measures that reduce the rate of reinfections and risks, techniques or measures have been promoted that allow the conservation of the abdomen, such as the Bogotá bag, which is one of the devices that have been described for temporary closure of the abdomen (10).

The "Bogota Bag" was described by Borraez in 1984 and continues to be one of the most used alternatives, due to its low cost and wide availability, it is one of the most important medical innovations of the 20th century, which has multiple indications, although the procedure is always the same, it allows giving a chance to life to patients in pathologies that were previously fatal (11, 12). The so-called Bogotá bag consists of fixing a sterile 3L irrigation bag to the fascia or skin. or similar material, which provides atraumatic coverage of the exposed viscera and allows visualization and permanent monitoring of their status (13)

There are several studies that report the effectiveness of the Bogotá Bag in the prevention of complications in patients with Abdominal Sepsis as it is an effective means of closing the abdominal wound and allowing rapid healing,

## Bogotá Bag as a Conservative Measure for Open Abdomen Secondary to Intra-Abdominal Sepsis

even though new alternatives have now emerged that they allow the conservation of the open abdomen, this procedure that is the focus of this review, continues to be the method that is most used in surgery, there are advantages that include

being an inert material, low cost and widely available; it can be fixed to the skin or fascia in order to protect the viscera and other tissues, among other advantages present in table 1 (14,15).

**Table 1. Utilities of the Bogotá bag for the preservation of the open abdomen secondary to intra-abdominal sepsis.**

It's a medium effective in closing the open abdominal wound
Avoid the complications due to open abdominal wounds or low closuretensión
Facilitates healing by granulation tissue or grafts
Effective because primary closure can be performed delayed abdominal wall successfully
Allows approximation of the abdominal wall from day 4 to 12 days after surgery.
Promotes decompression of intra-abdominal pressure preventing abdominal wall damage

### Materials and Methods

A detailed bibliographic search of the most relevant published information is carried out in the databases pubmed, scielo, medline, national and international libraries specialized in the topics covered in this review article. The following descriptors were used: Sepsis, open abdomen, Bogotá bag, conservation, intra-abdominal. The data obtained range between 15 and 30 records after the use of the different keywords. The search for articles was conducted in Spanish and English, limited by year of publication, and studies published from 2010 to the present were used.

### Results

The first bibliographic mention of the Open Abdomen (AA) technique dates back to 1897, once Andrew J. McCosh presented a detailed work on the abdominal sepsis procedure, and involved this technique for the performance of peritonitis, interpreting it as a huge abscess that, as such, had to be properly drained. From a modern perspective, the open abdomen technique becomes a therapeutic strategy in order to restore the anatomy and function of the abdominal wall. This treatment measure is divided into laparotomy, temporary abdominal closure and definitive closure of the abdominal wall, required in

pathologies such as abdominal trauma, peritonitis, aortic aneurysm, intestinal ischemia, necrotizing fasciitis, pancreatitis, intestinal occlusion, infiltrating tumor of the wall, severe burns and evisceration (16). Therefore, the open abdomen has the objective of abdominal containment, visceral protection and avoiding aponeurotic retraction (17). There are different techniques for the protection of the abdominal contents, which involve a temporary closure of the abdominal wall. The most studied are the Bogotá bag, Vacuum Pack or vacuum closure, closure only of the skin, Towel clip, polyethylene and skin bag, Wittman patch and use of prosthetic material very varied in its material and utility. Having reports of combinations and modifications of these techniques. (18) In 1984 at the San Juan de Dios Hospital in Bogotá, Colombia, they saw the need to leave the abdomen open in a patient undergoing several interventions who presented severe ileus. The wall defect was covered with a plastic sheet (polyvinyl) fixed to the aponeurosis, a procedure without precedent in the world. Today this element –viaflex bag– is known in international literature as the Bogotá Stock Exchange. This sheet is simply the one that contains hydroelectrolytic solutions for parenteral

## **Bogotá Bag as a Conservative Measure for Open Abdomen Secondary to Intra-Abdominal Sepsis**

administration or for urological irrigation in patients (19). Studies reveal that the management of the open abdomen contained with the Bogotá Bag is a simple technique for our environment due to its use with low-density material. cost as polyethylene obtaining satisfactory results, such as the one carried out in the Surgery Service of the Central Military Hospital where the Bogotá Bag was indicated for patients with abdominal sepsis, damage control, abdominal hypertension and second look (20). In addition, an observational, descriptive, longitudinal study of patients operated and managed with open abdomen in the II Chair of Surgical Clinic reveals that the multidisciplinary treatment of open abdomen with Borráz bag was used in the entire population studied, and in 4 of them, concomitantly with the vacuum aspiration system. Washing and bag change in the operating room were performed every 48 hours, with an average number of washings of 1.8 times (21). Likewise, the presentation of a case shows us the advantage of this therapeutic means, as in that of a man with a stab wound to the abdomen, in the region of the mesogastrium of  $\pm 5$  cm with exit of the omentum through it, by which underwent an exploratory laparotomy. After 12 days, an evolutionary ultrasound was performed, where multiple intra-abdominal abscesses were observed, so they resorted to deferring the closure and instead placing a Bogotá bag to which a low-pressure closed suction system (Hemovac) was attached. In this way, the patient had a favorable evolution and the abdomen was removed and definitively closed (22). Showing that the technique may be able to improve the serious clinical picture presented by patients with open abdomen, in addition to improving morbidity rates. -mortality associated with this technique. This is confirmed by an observational, descriptive, longitudinal, single-center and retrospective study carried out by Martinez et al. in patients admitted to the general surgery service of the Hospital de Especialidades, managed with some open abdomen technique over a period of 7 years, where they concluded that the Bogotá bag compared to the VAC system has the advantages of low cost, easily reproducible shorter hospital stay, shorter disability time, shorter time to definitive closure, as well as lower complication rate due to enteric fistula, however, what would make the difference would be the mortality rate, which is lower in the case of VAC therapy (23). Villafuerte et al. concluded that 40%

of the reviewed articles that show the effectiveness of the Bogotá Bag, where primary closure could be performed after a laparotomy, did not develop complications, allowed abdominal wall approximation, prevented abdominal wall damage, avoiding a increased retraction, representing an economical and useful alternative in the management of the open abdomen (24). On the other hand, a pilot study that included six patients who were managed with the Bogotá Bag and with a modification, five with abdominal sepsis and one with loss of the abdominal wall, which prevented its closure or coverage of the abdominal content, suggests that this modification achieves greater functionality of the Bogotá bag, highlighting the greater resistance and, consequently, early mobilization and ambulation and without risk of evisceration (18). The Bogotá bag technique (BB) is a method of tension-free temporary closure surgical technique (TAC) that covers the abdominal contents with a sterile bag of fluid. A retrospective cohort study describing the experience in the treatment of patients with BB, where they reviewed the medical records of 17 pediatric patients aged 0 to 18 years, found that the median duration of BB was 5 days and the median replacement of the bag was 2 days old. The median length of stay in the ICU was 10 days and the length of hospital stay was 27 days. Admission to the ICU and the BB procedure were well tolerated by 6 patients who were discharged without complications. Of the remaining 11 patients, 6 patients died during admission (35%) and the rest presented major complications not related to the BB but rather to the patient's primary disease (25). Another complementary study reports that the Bogotá bag was an effective means of closing open abdominal wounds and prevents complications due to open abdominal wounds or closure under tension, because in 36 (65.45%) cases managed with the Bogotá bag, scarring occurred by granulation tissue or skin grafts/flaps were applied and these patients developed hernia. Five (9.09%) patients developed a small bowel fistula that was treated conservatively. No patient developed complications due to exposure or abdominal compartment. There were 7 (12.8%) postoperative deaths due to the disease process and were not related to the closure technique (26).

### **Discussion**

## Bogotá Bag as a Conservative Measure for Open Abdomen Secondary to Intra-Abdominal Sepsis

Shabhay et al. (27) report that open abdomen closure techniques have evolved over time from protecting the abdominal viscera to complex fascia retraction prevention techniques. Silo bags, i.e. Bogota bags, are relatively cheaply available materials used as a method of temporary abdominal closure in resource-limited settings. Likewise, Ahmet concluded that the study proved to be effective as a temporary resource reserved for special surgical cases, associated with the morbidity and mortality inherent to the severity of the patients in which it can be used. It allowed the control of peritonitis and decompression of intra-abdominal pressure, preventing damage to the abdominal wall, avoiding an increase in its retraction (28), also coinciding with what was proposed by Aydincaan Akdur et al. Abdominal closure with a Bogotá bag in these patients is safe and effective in preventing abdominal compartment syndrome (29). The usefulness of this tool is extensive, as verified by the results of Balseca, which states that treatment with the Bogotá bag in patients with peritonitis due to acute appendicitis is a method that provides a lower rate of complications and mortality (30). In addition, it is one of the most used alternatives according to its indications, as reported by Enrico et al. The main indications for the use of OA were secondary peritonitis (32.5%), postoperative peritonitis (22.9%), and trauma (11.7%). The main Open Abdomen (OA) techniques used were commercial negative pressure wound therapy (49.6%) and the Bogotá bag (27.7%). Definitive closure of the abdomen was achieved in 82.4% of patients after  $6 \pm 7$  days of OA (31). However, other studies conclude that the artisanal VAC system is a safe, low-cost method with a low rate of complications. Which is recommended as the first option for the management of open abdomen surgery (32). The results of a report say that the frequency of enterocutaneous fistula was 2% in the group exposed to the modified VAC and 4% to the Bogotá Bag technique; the frequency of surgical site infection was 8% in the group exposed to the modified VAC and 22% to the Bogotá Bag technique; the frequency of residual abscess was 6% in the group exposed to the modified VAC and 18% to the Bogotá Bag technique; the frequency of abdominal hernia was 2% in the group exposed to the modified VAC and 4% to the Bogotá Bag technique, concluding that the Modified VAC technique is more effective than the Bogotá Bag technique to reduce

the rate of complications after damage control surgery in patients with abdominal trauma (33). The costs associated with the management of abdominal sepsis in the septic open abdomen vary greatly depending on the temporary abdominal closure used. If the length of hospital stay, the length of stay in the intensive care unit, and the number of surgeries required are the main parameters used to determine costs, the use of negative pressure therapy with 0 saline instillation .9% reduces costs by nearly 50% compared to conventional negatives (34).

### Conclusion

The Bogotá Bag technique, like other methods described for abdominal wall closure, represents a simple and effective way in abdominal surgery, it can be considered as a conservative measure against open abdomen secondary to intra-abdominal sepsis due to its ability to prevent complications in these patients. In addition to being an inexpensive, available and easy-to-place material, it allows direct observation of the abdominal cavity and does not appear to affect definitive closure, even promoting wound healing and rapid healing with behavior that does not involve adhesions with the viscera. That is why its use has increased in frequency over the years and doctors have implemented it in surgical procedures in intra-abdominal sepsis with really promising results that increase the quality of life of the patient.

### References

1. Valverde Y. Fundamentos epidemiológicos, fisiopatológicos y clínicos de la sepsis en la población infantil. MEDISAN. 2011; 15(8):1156-1165 [el 8 de diciembre 2021] Disponible en <http://scielo.sld.cu/pdf/san/v15n8/san15811.pdf>
2. Phillip R, Levy M, Rhodes A, Annane D, Gerlach H, Opal S, et al. Campaña para sobrevivir a la sepsis: recomendaciones internacionales para el tratamiento de sepsis grave y choque septicémico, 2012. Revista Critical Care Medicine 2013; 36(4):250-256. [Accesado el 8 de diciembre 2021] Disponible en <http://www.survivingsepsis.org/SiteCollectionDocuments/Guidelines-Spanish.pdf>
3. Carmona-Sánchez R. Revista de Gastroenterología de México [Internet].2018, May. [citado 8 de diciembre de 2021]. Disponible en: <http://www.revistagastroenterologi>

## Bogotá Bag as a Conservative Measure for Open Abdomen Secondary to Intra-Abdominal Sepsis

- amexico.org/es/sepsisabdominal/articulo/X0375090611252836/%7D
- Sartinelli, M, Viale, P, Catena, F. WSES Guidelines for Management of Intraabdominal Infections. *World Journal of Emergency Surgery*. 2013; 8(13)
  - Pallas L. Interleukina G. Valor pronóstico de mortalidad y fracaso multiorgánico en el paciente crítico. [Tesis para la obtención del grado de doctor en Medicina y Cirugía] Valencia: Universidad de Valencia; 2013 [Accesado el 8 de diciembre 2021] Disponible en <http://roderic.uv.es/handle/10550/34696>.
  - Pertuz-Meza, Yolima, Celenny Perez-Quintero, and Yadira Pabón-Varela. "Aspectos epidemiológicos de la sepsis, en unidades de cuidados intensivos Santa Marta, Colombia." *Duazary* 13.2 2016: 126-132.
  - Gorordo-Delsol, L., et al. "Sepsis abdominal: fisiopatología, diagnóstico y tratamiento." *Revista Mexicana de Cirugía del Aparato Digestivo* 4 2015: 110-117.
  - Toscano, Elena, et al. "Toxicidad hepática inducida por los nuevos fármacos inmunosupresores." *Gastroenterología y Hepatología* 33.1 ,2010,: 54-65.
  - Arenas-Márquez H. Manejo del abdomen abierto. Los mejores resultados. *Cir Gen*. 2010;32:S43-45.
  - Carrillo E, Carrillo J, Carrillo L. Estudio epidemiológico de la sepsis en unidades de terapia intensiva mexicanas. *Cir Cir*. [Internet] 2010, May. [Citado el 8 de dic de 2021]; 77(4) pp: 301-308. Disponible desde: <http://www.medigraphic.com/pdfs/circir/cc-2009/cc094h.pdf>
  - Vásquez Díaz, Lenin Denis. "Evaluación del uso de la técnica bolsa de bogotá en el servicio de cirugía del Hospital Regional Honorio Delgado en el periodo Enero 2010-Diciembre 2015." 2016.
  - Manterola, Carlos, Javier Moraga, and Sebastian Urrutia. "Laparostomía contenida con bolsa de Bogotá. Resultados de una serie de casos." *Cirugía Española* 89.6 ,2011: 379-385.
  - Rodríguez, Shyrle Lisbeth Vaca, et al. "Utilización de bolsa de Bogotá en peritonitis secundaria y abdomen abierto." *RECIMUNDO: Revista Científica de la Investigación y el Conocimiento* 2.3 ,2018: 287-296.
  - Felipe, A. Manejo de Abdomen Abierto: Nuevo Concepto en Cirugía Abdominal. Visto en: <http://med.javeriana.edu.co/publi/vniversitas/serial/v44n1/0004%20abdomen.pdf> [revisado 8 diciembre 2021].
  - Soroa, P. La bolsa de Bogotá, Aporte Médico Trascendente. Visto en: <http://dcuba.net/la-bolsa-de-bogota-aporte-medico-trascendente/> [revisado 8 diciembre 2021]
  - Wainstein, D. L., and J. E. S. I. C. A. Langer. "Abdomen abierto. Indicaciones, manejo y cierre." Galindo F y col. *Enciclopedia de Cirugía Digestiva*. Buenos Aires (2014).
  - Wainstein, Daniel E., et al. "Manejo del abdomen abierto mediante vacío con y sin tracción dinámica de la pared abdominal." *Revista argentina de cirugía* 109.3 (2017): 122-128.
  - Mejía Rendón, Gabriel, and Sonia Iliana Mejía Pérez. "Bolsa de Bogotá resistente en abdomen abierto." *Cirujano general* 34.1 (2012): 54-57.
  - Zavala, Melvin Castillo, and Jorge Alberto Sierra. "Bolsa de Bogota: una solución para el cierre abdominal temporal." *Revista Médica de los Post Grados de Medicina UNAH* Vol 9.1 (2006): 34.
  - Arias, Hernando R. Cardozo, et al. "Experiencia en el manejo del Abdomen abierto contenido con Bolsa de Bogotá en el Hospital Militar Central de las Fuerzas Armadas." *SOCIEDAD PARAGUAYA DE CIRUGÍA* (2021): 9.
  - Acosta, Rosa Ferreira. "Resultados en el manejo del abdomen abierto. Nuestra experiencia." *Anales de la Facultad de Ciencias Médicas*. Vol. 45. No. 1. 2012.
  - Vilar, Katia Vilar. "Manejo del Abdomen Abierto mediante la técnica de Bolsa de Bogotá; Modificada." *Investigaciones Medicoquirúrgicas* 12.1 (2020).
  - Martínez Abonce, Jefferson Matt. "Manejo de abdomen abierto con diferentes técnicas, estudio comparativo." (2017).
  - Villafuerte Montoya, Katherine Stefanny, and Miriam Zanabria Román. "EFICACIA DE LA BOLSA DE BOGOTA EN LA PREVENCIÓN DE COMPLICACIONES EN PACIENTES CON SEPSIS ABDOMINAL." (2018).
  - Neeman E, Heiman Newman N, Cavari Y, Feinstein Y, Fuxman Y, Lazar I. Bogota Bag Temporary Abdominal Closure Surgical

## Bogotá Bag as a Conservative Measure for Open Abdomen Secondary to Intra-Abdominal Sepsis

- Technique in Children: A 15-Year Single Center Experience. *Isr Med Assoc J.* 2020 Jan;22(1):43-47. PMID: 31927805.
26. Muhammad Y, Gondal KM, Khan UA. Use of the "bogota bag" for closure of open abdominal wound after exploratory laparotomy - our experience at Mayo Hospital Lahore. *J Pak Med Assoc.* 2016 Aug;66(8):980-3. PMID: 27524532.
27. Shabhay A, Shabhay Z, Chilonga K, Msuya D, Mwakyembe T, Chugulu S. Standard Urine Collection Bag as an Improvised Bogotá Bag as a Temporary Abdominal Closure Method in an Open Abdomen in Preventing Abdominal Compartment Syndrome. *Case Rep Surg.* 2021 Jan 29;2021:6689000. doi:10.1155/2021/6689000. PMID: 33575055; PMCID: PMC7864741.
28. Rencüzoğulları, Ahmet, et al. "Comparison of early surgical alternatives in the management of open abdomen: a randomized controlled study." *Turkish Journal of Trauma and Emergency Surgery* 21.3 2015: 168-174.
29. Akdur A, Kirnap M, Ozcay F, Sezgin A, Ayvazoglu Soy HE, Karakayali Yarbug F, Yildirim S, Moray G, Arslan G, Haberal M. Large-for-size liver transplant: a single-center experience. *Exp Clin Transplant.* 2015 Apr;13 Suppl 1:108-10. PMID: 25894137.
30. Balseca Suárez, Galo Simón. Índice de sobrevida en pacientes que se hayan realizado la técnica de bolsa de Bogotá, en apendicitis complicada con peritonitis entre el año 2016 y 2018 en el Hospital General Guasmo Sur. Diss. Universidad de Guayaquil. Facultad de Ciencias Médicas. Carrera de Medicina, 2019.
31. Cicuttin E, Ansaloni L, Ceresoli M, Fugazzola P, Tomasoni M, Sartelli M, Catena F, Coccolini F; Italian IROA Study Group. Trends in open abdomen management in Italy: a subgroup analysis from the IROA project. *Updates Surg.* 2020 Mar;72(1):171-177. doi: 10.1007/s13304-019-00687-4. Epub 2019 Oct 16. PMID: 31621034.
32. Rodríguez, Mg Luis Alfredo Triveño, Md José Jáuregui Sagástegui, and Mg José Gustavo Gonzales Zavala. "EFICACIA DEL VAC ARTESANAL EN EL MANEJO DEL ABDOMEN ABIERTO EN EL HOSPITAL BELEN TRUJILL." *Revista Médica de Trujillo* (2014).
33. Campos, Huamán, and Dante Wualdembar. "Efectividad del VAC-modificado y bolsa de Bogotá en la disminución de las complicaciones post cirugía de control de daños." 2021.
34. Betancourt AS, Milagros GC, Sibaja P, Fernandez L, Norwood S. Cost evaluation of temporary abdominal closure methods in abdominal sepsis patients successfully treated with an open abdomen. Should we take temporary abdominal closure methods at face value? Health economic evaluation. *Ann Med Surg (Lond).* 2020 Jun 9;56:11-16. doi: 10.1016/j.amsu.2020.06.007. PMID: 32566220; PMCID: PMC7296327.

**How to cite this article:** Cordoba, D. A. L. ., Cardenas, S. M. F. ., Bravo, O. O. L. ., Castro, C. A. T. ., Anguila, J. J. M. ., Castro, J. P. M. ., Valenzuela, C. O. P. ., & Pastrana, J. F. C. . (2022). Bogotá Bag as a Conservative Measure for Open Abdomen Secondary to Intra-Abdominal Sepsis. *Journal of Medical Research and Health Sciences*, 5(4), 1886–1893. <https://doi.org/10.52845/JMRHS/2022-5-4-5>