



Research Article

Open Access Journal



Warren Technique for the Correction of Portal Hypertension in Pediatric Patients

Jorge Julian Mendoza Anguila^{1*} , Conrado de Jesús Orozco Alvaran², Andrés Enrique Jaraba Miranda³, Maria Fernanda Riaño Rojas⁴, Ana María Garcés Pérez⁵, Ana María Pineda Navarro⁶, Frank David Almenares Gómez⁷, Nataly Zuluaga Villada⁸

Corresponding Author: Jorge Julian Mendoza Anguila

¹General Physician, Universidad Cooperativa de Colombia, Sede Santa Marta

²General Physician, Universidad de Antioquia

³General Physician, Universidad del Sinú, Montería

⁴General Physician, FUCS. Fundación Universitaria de Ciencias de la Salud.

⁵General Physician, Universidad del Magdalena.

⁶General Physician, Universidad Metropolitana, Barranquilla

⁷General Physician, Universidad del Magdalena

⁸General Physician, Universidad de Manizales

Abstract:

the portal vein formed by the union of the superior mesenteric vein with the blood flow from the small intestine and the pancreas, the splenic and in most cases the inferior mesenteric and gastric veins, the portal vein is responsible for draining the splanchnic flow to the liver which is used for the processing and metabolism of products derived from intestinal absorption; portal venous pressure is slightly higher than the pressure of the inferior vena cava and ranges between 0-11mmHg, when there is obstruction or resistance to venous flow in the splanchnic bed and the right atrium due to the compromise of the vascular lumen, this alteration produces an increase in the pressure of the portal vein, which leads to portal hypertension (PHT) which is defined as an increase in hydrostatic pressure in the portal system. The surgical procedure to treat this pathology consists of diverting the high pressure from the portal venous system to the systemic circulation (portosystemic shunt) or ideally to the portal circulation (mesenteric portal shunt of Rex or porto-portal shunt to the right portal vein). Portosystemic shunts are divided into porto-caval shunts and selective shunts such as Warren's distal splenorenal shunt and proximal splenorenal shunt. This procedure has given satisfactory results if you want to selectively decompress gastroesophageal varices while preserving portal perfusion of the liver, as well as the results that this procedure will be chosen over the years for its reliability and low mortality rate. and morbidity.

Keywords: Portal hypertension, pediatrics, Warren technique, selective diversion, shunt.

Copyright : © 2021 The Authors. Published by Medical Editor and Educational Research Publishers Ltd. This is an open access article under the CC BY-NC-ND license (<https://creativecommons.org/licenses/by-nc-nd/4.0/>).



Introduction

The portal vein is one of the most important abdominal veins and also the main vessel of the portal system which begins and ends in the capillaries, the portal vein formed by the union of the superior mesenteric vein with the

blood flow of the small intestine and the pancreas, the splenic and in most cases the inferior mesenteric and gastric veins, the capillaries that give rise to this come from the abdominal territory and once the path through the sinusoids has

Warren Technique for the Correction of Portal Hypertension in Pediatric Patients

elapsed, the venous drainage occurs through the suprahepatic veins towards the inferior vena cava and later it returns to the heart, the portal vein is responsible for draining the splanchnic flow to the liver which is used for the processing and metabolism of products derived from intestinal absorption. (1)

The portal venous system is of low pressure, it provides 75% of the hepatic blood flow and supplies the liver with oxygen, nutrients and hormones, the portal venous pressure is slightly higher than the pressure of the inferior vena cava and ranges between 0-11mmHg, when there is an obstruction or resistance to venous flow in the splanchnic bed and the right atrium due to the compromise of the vascular lumen, this alteration produces an increase in the pressure of the portal vein, which leads to portal hypertension (PHT), which is defined as an increase in hydrostatic pressure in the portal system. This increase determines that the pressure gradient between the portal vein and the vena cava rises above the normal range (2-5 mmHg). a portal venous gradient between 5-10mmHg is considered pre clinical portal hypertension and if it exceeds 10mmHg it is considered clinically significant, this is a clinical syndrome characterized by increased pressure values in the portal venous drainage system of the digestive system, at the pathophysiological level, this syndrome is produced by an increase in blood flow and flow resistance at the level of the portal territory, or the combination of both phenomena, thus causing a pressure above 10-12 mmHg, where this increase will be transmitted in a retrograde manner, consequently producing clinical alterations that threaten the patient's life such as the appearance of collateral circulation also called varices and extravasation of peritoneal fluid (ascites), a series of pathological changes and complications such as splenomegaly, hypersplenism are also observed, gastrointestinal bleeding, thrombocytopenia, portal gastropathy and sign clinical signs of portopulmonary syndromes. (2)

This pathological entity, according to the clinical presentation, is classified as cirrhotic (associated with elevated hepatic venous pressure due to increased sinusoidal resistance) or non-cirrhotic (characterized by mild or moderate pressures and normal liver function) and according to the anatomical site. where the obstruction or resistance of the venous flow of the portal vein

occurs, it is classified as pre-hepatic, intra-hepatic, post-hepatic and arterial-portal hypertension, in turn the intra-hepatic also called hepatic are classified as presinusoidal, sinusoidal and post sinusoidal, according to the literature the most frequent form of presentation in pediatrics is pre-hepatic given by a cavernous degeneration of the portal vein or also given by a thrombosis of the same, manifested with alterations such as splenomegaly in 91%, hemorrhage digestive 83% and only 3% have ascites, it is suggested that the disease manifests before the age of 6 in most cases and rarely occurs before 12 months. (1,2)

This disease is not considered in the differential diagnosis of pediatrics, so it can develop silently for many years or even be ignored. Therefore, when faced with clinical manifestations of upper gastrointestinal bleeding or splenomegaly in children, portal hypertension should be highly suspected for further evaluation using Doppler ultrasound and CT angiography and other imaging tests that are very useful for evaluating the vascular anatomy. (3)

The surgical procedure to treat this pathology consists of diverting the high pressure from the portal venous system to the systemic circulation (portosystemic shunt) or ideally to the portal circulation (mesenteric portal shunt of Rex or porto-portal shunt to the right portal vein). Portosystemic shunts are divided into porto-caval shunts and selective shunts such as Warren's distal splenorenal shunt and proximal splenorenal shunt. (4)

Among the surgical procedures used for the treatment of this pathology is the distal splenorenal shunt described in 1967 by Warren and Zeppa (technique known as the Warren surgical procedure), which introduced the concept of selectivity for the first time. special decompression that drains the gastroesophageal and splenic veins into the systemic circulation, initially in selected patients, in whom life-threatening bleeding episodes dominate, without ascites, and without full hepatic blood flow. Since then, this technique has been reported to have achieved excellent results in controlling bleeding events. Complications were few in selected patients and most of them were adults. This is a technique where a dissection of the splenic vein is performed below the pancreas, selecting it at its entry into the portal vein and end-to-side anastomosis of the splenic vein to the left renal

Warren Technique for the Correction of Portal Hypertension in Pediatric Patients

vein found immediately below. This technique allows decompression of the portal venous system, of esophageal varices, preserves the conditions of the spleen and allows portal flow to be maintained, allowing patients with HPT with thrombosis of the portal vein or biliary cirrhosis survival at 5, 10 and 20 years. greater than 85% with bleeding and less surgical time and likewise avoids liver failure a posteriori and likewise considerably reduces the need for a liver transplant, taking into account the above, this Warren procedure has excellent results in patients with normal liver function in terms of bleeding events with the presence of very few complications, which is of vital importance since these events are the ones that most put the life of the pediatric patient at risk. (3,4,5)

Methodology:

A detailed bibliographic search of the required information that was published from 2012 to 2021 is carried out in the scielo, Update, medline, pubmed, Elsevier, and various national and international libraries databases. The following

descriptors were used: portal hypertension, pediatrics, Warren technique, selective diversion, shunt. The data obtained ranges between 9 - 18 records after the use of the different keywords, 13 articles were used to carry out this document. The search for articles was conducted in Spanish and English, limited by year of publication, and studies published from 2012 to date that had information related to the Warren Technique for the correction of portal hypertension in pediatric patients were used.

Results:

Fourteen patients with extrahepatic portal vein thrombosis (DVT) and refractory complications of portal hypertension (PH) underwent distal splenorenal bypass surgery in a Leuven hospital. The age was 15 years and the male/female ratio was 7/7. The distal splenorenal bypass (DSRS) was performed following the methods published by Dean Warren, accompanied by selective decompression of transsplenic varices and ensuring the maintenance of portal perfusion of the liver (Fig 1).

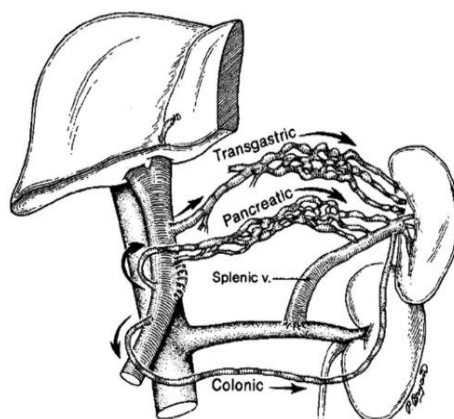


Fig 1. Warren shunt schematic. The technique is performed by lowering the splenic vein without tension or kinking to the anterior/superior surface of the left renal vein.

Taken from: Henderson JM, Millikan WJ Jr, Galloway JR. Emory's view of the distal splenorenal shunt in 1990. *Am J Surg.* 1990; 160: 54-59

It was found that this procedure gave satisfactory results if it is desired to selectively decompress gastroesophageal varices while preserving portal perfusion of the liver, as well as the results that this procedure over the years will be chosen for its reliability and low rate. of mortality and morbidity (6), taking into account that the creation of a

DSRS provides a high-flow, low-pressure shunt in the upper left quadrant of the abdomen that will control the bleeding of esophageal varices refractory to medical or endoscopic treatment (8).

In Germany at a Beijing Hospital, from June 2008 to January 2017, 12 of 122 children with extrahepatic portal vein obstruction (EHPVO) underwent a second operation due to graft stenosis and occlusion after Rex shunt, comparing thus, the technique with the distal splenorenal Warren shunt was performed in children who were not suitable

Warren Technique for the Correction of Portal Hypertension in Pediatric Patients

for the re-Rex shunt due to a narrowed left portal vein (9).

Five children underwent Warren shunt, of whom one child had a patent bypass vein with intrahepatic portal dysplasia. After Warren's referral, no patient was placed on a special low-nitrogen diet and received enteral lactulose (9).

The postoperative incidence of rebleeding in children with a Warren shunt was significantly lower than that of children with a re-Rex shunt (20% vs. 62.5%, $P = 0.027$). The postoperative incidence of esophageal varices was significantly lower in children with Warren shunt than in children with re-Rex shunt (20% vs. 75%, $P = 0.015$). There was no significant difference between the two groups in the length of follow-up ($P = 0.804$). The bypass vein patency rate in children who underwent a re-Rex shunt was lower than that of children with a Warren shunt (50% vs 100%).

In Ecuador, an 8-year-old male patient, who had no pathological history, went to the hospital for presenting an evident abdominal mass below the costal margin on physical examination, the laboratories revealed leukopenia and thrombocytopenia. During hospitalization, the patient presented upper gastrointestinal bleeding with hemodynamic repercussions, with hemoglobin values of 7gr/dL. Treatment with blood transfusion and endoscopy was established, which revealed the presence of grade IV esophageal varices. Doppler ultrasound and magnetic resonance angiography confirmed portal cavernomatosis, extensive thrombosis of the distal splenic vein, and ascites. The patient underwent a selective distal splenorenal bypass according to the Warren surgical technique with end-to-side anastomosis of the splenic vein to the renal vein. As a result, an improvement was obtained in the seven days of hemoglobin, leukocytes and platelets, spleen size decreased by 50% (2).

Discussion:

According to the results of this article, the Warren technique has good results in the case of selective decompression of gastroesophageal varices while preserving portal perfusion of the liver. In addition, this procedure has good reliability and low mortality and morbidity rates; In addition, it was found that the Warren technique, compared to other techniques such as the rex shunt, has a lower

incidence of bleeding and the appearance of postoperative varices (8,9).

According to a study conducted in Italy in 2012, children with a thrombosed left portal vein within the Rex recessus who cannot benefit from MRB should continue in a conventional endoscopic program and conservative management, as this also provides satisfactory long-term results through the prevention of bleeding; but these children might become candidates for portosystemic shunt surgery when complications cannot be managed medically or endoscopically, and our preference is for a selective shunt, such as a Warren shunt, to preserve some hepatopetal flow through the cavernoma while preserving the hepatotrophic effect of mesenteric blood; Other teams use non selective H-type leads such as mesocava and lateral splenorenal; in this scenario and obtain excellent clinical results, possibly because type H shunts may not cause complete diversion of portal flow. Rather, there may be a partial bypass by using a long vein interposition graft with a degree of resistance, and keeping in mind that surgery without bypass should be strictly avoided, at least as primary surgical therapy, as it has little effect on portal pressure and can even seriously worsen the condition of the abdominal cavity for future surgery. (eleven).

The Warren shunt involves division of the splenic vein and anastomosis of the distal stump into the left renal vein, thereby preserving mesenteric and portal blood flow to the liver. However, with the complex collateralization and networks of the splanchnic venous system, some communications always persist, and this "selective" shunt has been shown to progressively "centralize" over time. This option decreases the size of the spleen, improves hypersplenism, and normalizes platelet and white blood cell counts. Selective shunts have been used successfully to treat variceal hemorrhage and hypersplenism and have been shown to reduce postoperative encephalopathy with equivalent long-term mortality and rebleeding rates, and long-term patency rates of 90% have been reported (11, 12).

According to a 2020 article, routine preoperative retrograde portography imaging can improve correct identification of these individuals and thus improve long-term Rex shunt patency rates; Furthermore, as previous studies suggest, the Warren shunt and the side-to-side splenorenal shunt appear to be rational options with

Warren Technique for the Correction of Portal Hypertension in Pediatric Patients

satisfactory long-term patency and symptom relief, if the mesoportal shunt is not feasible (13).

Conclusion:

Portal hypertension is not a usual diagnosis in pediatrics, so it can progress silently, leading to complications. When the diagnosis is obtained, there are different treatments that can be used, including the Warren technique, which, according to different Studies have shown that it is a treatment with good results in the case of selective decompression of gastroesophageal varices while preserving portal perfusion of the liver. In addition, this procedure has good reliability, a low mortality rate, morbidity, and a decrease in postoperative complications.

References:

1. Jiménez CE, Randial L, Silva I, Hossman-Galindo M, Bravo M, Moreno O. Trombosis venosa portal extrahepática, manejo quirúrgico con derivación meso-Rex. Serie de 3 casos. *Rev Colomb Cir.* 2021;36:98-109. <https://doi.org/10.30944/20117582.574>
2. Ruíz S, Marcano L, Quizhpi G, Córdova F, Juma M, et al. Caso Clínico: Derivación Esplenorenal Distal Selectiva en la Hipertensión Portal Prehepática. *Rev Med HJCA* 2015; 7(2): 167-172. <http://dx.doi.org/10.14410/2015.7.2.cc.32>
3. Bosch J, tratamiento de la hipertensión portal. *Gastroenterol Hepatol.* 2010;33
4. Sosa R, Hernandez E, Ramirez C, Salazar P, Lopez A, Manejo quirúrgico de la hipertensión portal pre-hepática en pediatría. Reporte preliminar de 6 casos, *Rev Guatem Cir*, 2018 (24).
5. Vidales E, Medina A, Santos K, experiencia en el manejo de hipertensión portal con el procedimiento de warren en pacientes pediátricos, *Rev Mex Cir Ped*, 2015 Vol XIX.
6. Van Praet, K. M., Ceulemans, L. J., Monbaliu, D., Aerts, R., Jochmans, I., & Pirenne, J. (2020). An analysis on the use of Warren's distal splenorenal shunt surgery for the treatment of portal hypertension at the University Hospitals Leuven. *Acta Chirurgica Belgica*, 1–7. doi:10.1080/00015458.2020.1726099
7. Henderson JM, Millikan WJ Jr, Galloway JR. La perspectiva de Emory de la derivación esplenorenal distal en 1990. *Am J Surg.* 1990; 160: 54–59
8. Evans S, Stovroff M, Heiss K, et al. Derivaciones esplenorrenales distales selectivas para la hemorragia intratable por várices en la hipertensión portal pediátrica. *J Pediatr Surg.* 1995;30:1115–1118.
9. Zhang, J.-S., Li, L., & Cheng, W. (2018). Surgical treatment for rebleeding caused by bypass failure after Rex shunt: re-Rex shunt or Warren shunt? *Pediatric Surgery International*, 34(5), 521–527. doi:10.1007/s00383-018-4246-0
10. Cortez, A. R., Kassam, A.-F., Jenkins, T. M., Nathan, C. J., Nathan, J. D., Alonso, M. H., ... Bondoc, A. J. (2019). The role of surgical shunts in the treatment of pediatric portal hypertension. *Surgery.* doi:10.1016/j.surg.2019.05.009
11. De Ville de Goyet, J., D'Ambrosio, G., & Grimaldi, C. (2012). Surgical management of portal hypertension in children. *Seminars in Pediatric Surgery*, 21(3), 219–232. doi:10.1053/j.sempedsurg.2012.05
12. de Ville de Goyet J, D'Ambrosio G, Grimaldi C. Surgical management of portal hypertension in children. *Semin Pediatr Surg.* 2012 Aug;21(3):219-32. doi:10.1053/j.Sempedsurg.2012.05.005. PMID: 22800975.
13. Luoto TT, Koivusalo AI, Pakarinen MP. Long-term Outcomes and Health Perceptions in Pediatric-onset Portal Hypertension Complicated by Varices. *J Pediatr Gastroenterol Nutr.* 2020 May;70(5):628-634. doi: 10.1097/MPG.0000000000002643.PMID : 31990868.

How to cite this article: Anguila, J. J. M. , Alvaran, C. de J. O. , Miranda, A. E. J. , Rojas, M. F. R. , Pérez, A. M. G. , Navarro, A. M. P. , Gómez, F. D. A. , & Villada, N. Z. . (2022). Warren Technique for The Correction of Portal Hypertension in Pediatric Patients. *Journal of Medical Research and Health Sciences*, 5(4), 1894–1898. <https://doi.org/10.52845/JMRHS/2022-5-4-6>