



## Gluteoplasty Implants And Lipotransfer Technique

Aristides Arellano MD, FICS.<sup>1</sup>, Anja Arellano MD, FACS.<sup>2</sup>, Dafne Arellano MD.<sup>3</sup>

Corresponding Author: Aristides Arellano



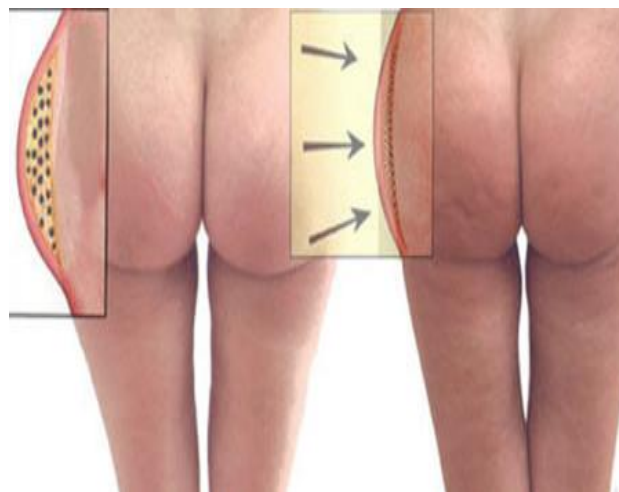
Copyright : © 2021 The Authors. Published by Medical Editor and Educational Research Publishers Ltd. This is an open access article under the CC BY-NC-ND license (<https://creativecommons.org/licenses/by-nc-nd/4.0/>).

### Gluteoplasty, what is it for?

It is a surgery that improves the projection, shape and volume of the buttocks. Gluteoplasty (from the Greek *gloutós* and *grupa* or *plassein* meaning to shape), which denotes the plastic surgery and fat grafting procedures for the correction and shaping of the congenital, acquired and traumatic defects of the buttocks. Besides the anatomy of the gluteal region, we can re-shape the gluteal

area, performing an aesthetic enhancement, by augmentation or reduction of the buttocks contour

The corrective procedures for buttock augmentation and buttock repair include the surgical placement of a gluteal implant (buttock prosthesis), liposculpture (fat transfer and liposuction) and body contouring (surgery and liposculpture) to resolve the patient's particular defects or deformities of the gluteal region.



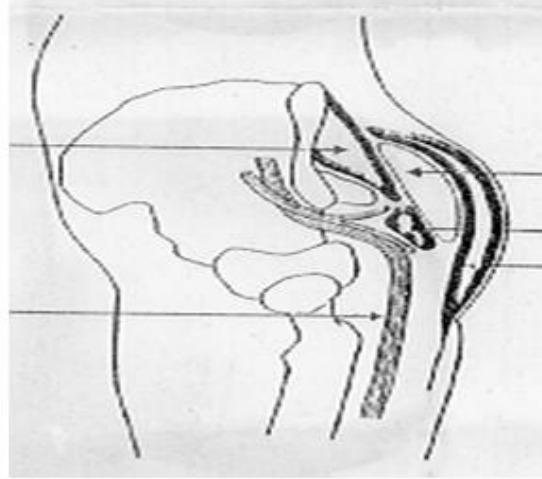
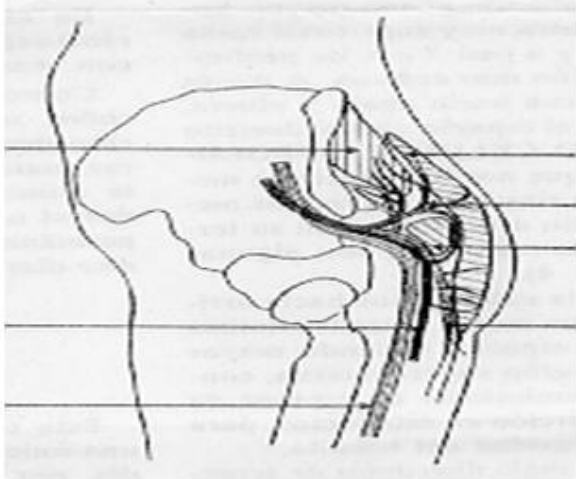
Also, in the praxis of sexual reassignment surgery, the prosthetic and liposculpture augmentation of the buttocks can be performed on transsexual and transgender women to enhance the anatomic curvature of the gluteal region in order to establish

the markedly feminine buttocks and hips that project more (to the rear and to the side) than masculine hips.

## Gluteoplasty Implants And Lipotransfer Technique

The functional purpose of the buttock's musculature is to establish a stable gait (balanced walk) for the man or the woman who requires the surgical correction of either a defect or a deformity of the gluteal region; therefore, the restoration of anatomic functionality is the therapeutic consideration that determines which gluteoplasty procedure will effectively correct the damaged muscles of the buttocks.

The applicable techniques for surgical and correction include the surgical emplacement of gluteal implants, autologous tissue-flaps, the excision of damaged tissues, fat placement, and liposuction to correct the defect or deformity caused by a traumatic injury (blunt, penetrating, blast) to the buttock's muscles (gluteus maximus, gluteus medius, gluteus minimus), and any deformation of the anatomic contour of the buttocks.

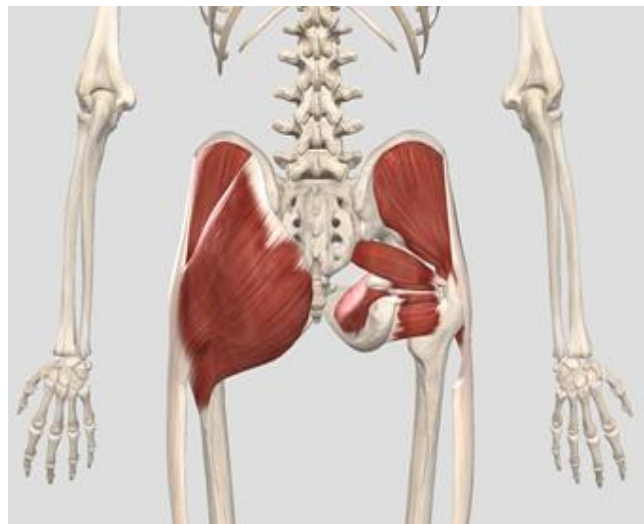

Likewise, the corrective techniques apply to correct the sagging skin of the body, the muscle and bone deformities presented by a former obese patient, who has undergone a massive weight loss (MWL) or bariatric surgery procedure.

### Surgical Anatomy of the Buttocks

The surgical anatomy of the gluteus maximus muscle, as considered for a buttock-lift surgery.

Anatomically, each buttock's mass is composed mainly of two muscles: gluteus maximus and gluteus medius, both covered by a layer of adipose body fat. The upper aspects of the buttocks end at the iliac crest (the upper edges of the wings of the ilium, and the upper lateral margins of the greater pelvis); the lower aspects of the buttocks end at the horizontal gluteal crease, where the buttocks anatomy joins the rear, upper portion of the thighs.

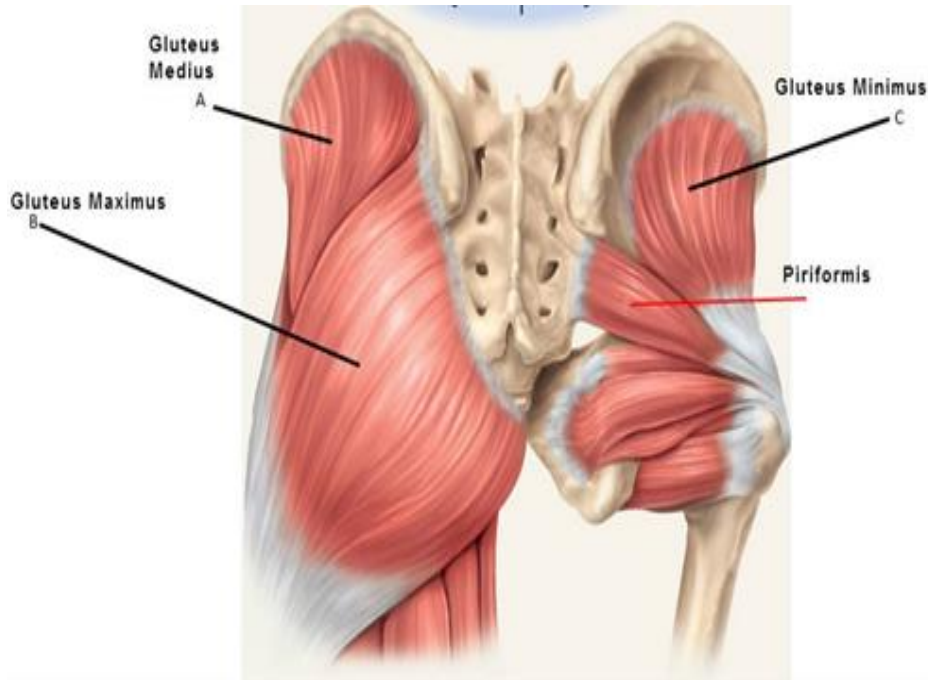


## Gluteoplasty Implants And Lipotransfer Technique

The gluteus maximus muscle has two points of insertion: the superior portion of the coarse line at the thigh bone, and the superior portion of the iliotibial tract. The left and the right gluteus maximus muscles (the butt cheeks) are vertically divided by the intergluteal cleft (the butt-crack) which contains the anus.

The gluteus maximus is a large and thick muscle (6–7 cm) located on the sacrum, which is a large triangular bone located at the base of the vertebral

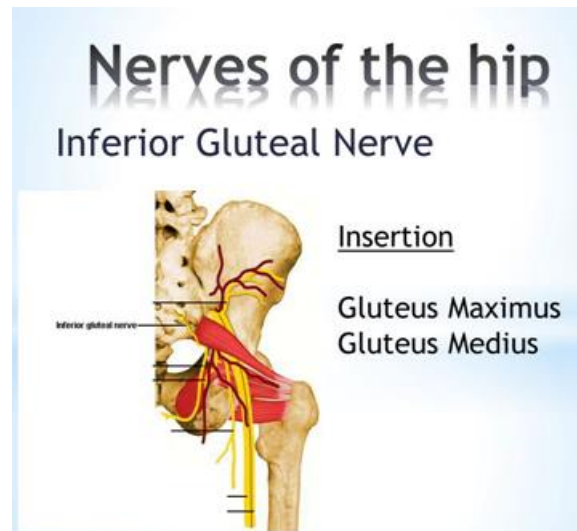
column, and at the upper- and back-part of the pelvic cavity, where it is inserted (like a wedge) between the two hip bones. The upper part of the sacrum is connected to the final lumbar vertebra (L5), and to the bottom of the coccyx (tailbone). At its origin, the gluteus maximus muscle extends to include parts of the iliac bone, the sacrum, the coccyx, the sacrosciatic ligament, and the tuberosity of the ischium.



Like all the muscles of the pelvis, the gluteus maximus originates in the pelvis; however, it is the only pelvic muscle that is not inserted into the trochanter (head of the femur), and is approximately aligned with the femur and the fascia lata (the deep fascia of the thigh); the tissues of the gluteus maximus covering only the back, the lateral face of the trochanter, and not forming a pouch (purse) that faces the inside of the thigh.

### Innervation

The motor innervation of the gluteus maximus muscle is performed by the inferior gluteal nerve and extends from the pelvis to the gluteal region, then goes through the greater sciatic foramen from behind and to the middle to then join the sciatic nerve. The inferior gluteal nerve divides into three collateral branches: the gluteus branch, the perineal branch, and the femoral branch. The first ramification, the gluteus branch, is a branch nerve that is very close to the emergence of the inferior gluteal nerve to the area, next to the inferior border of the pyramidalis muscle.



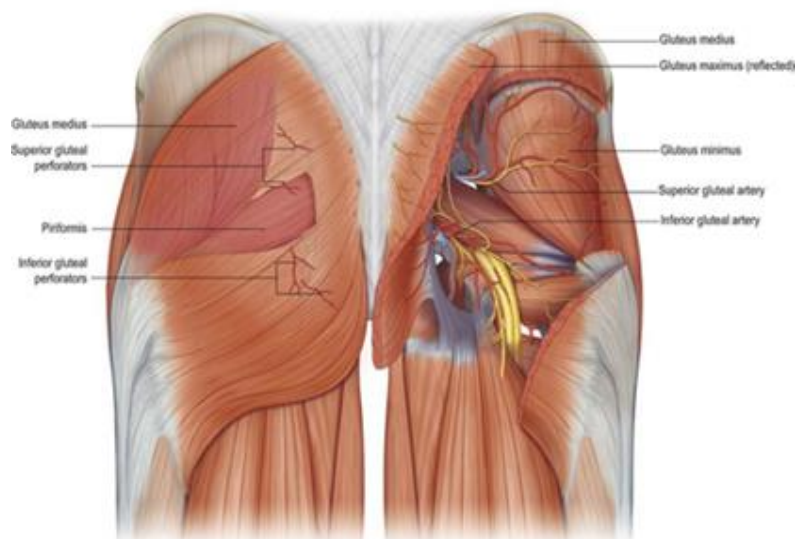
As it arises, the inferior gluteal nerve then divides into four (4) or more fillets (bands of nerve fibers) that travel (in a crow's-foot configuration) between the gluteus maximus muscle and its anterior fascia; the thickest nerve-bands are the superior-most and the inferior-most fillets. The superior-most fillet runs almost vertically, near the sacrum, and innervates the superior portion of the gluteus muscle; the inferior-most fillet, which has the greatest caliber, travels very close and parallel to the sacrotuberous ligament; the inferior-most fillet provides fine-gauge branch-nerve ramifications that innervate the gluteus muscle through its anterior face.

In surgical and body contouring praxis, the plastic surgeon creates the implant-pocket, either for the gluteal prosthesis or for the injections of autologous fat: by undermining the gluteus maximus muscle with a dissection technique that

avoids the sacrum, the sacrotuberous ligament, and the tuberosity of the ischium, which, if accidentally cut, might isolate the posterior portion of the muscle and lead to denervation, the loss of nerve function and of innervation.

### Vascularization

The superior gluteal artery, the inferior gluteal artery, the superior gluteal veins, and the inferior gluteal veins irrigate the gluteus maximus muscle with arterial and venous blood. The vascularization, the entrance of the blood vessels to the muscle tissues, occurs at the anterior face of the muscle, very close to the sacrum. As the arteries and the veins enter the mass of the gluteal muscle, they divide into narrower blood-vessel ramifications (configured like the horizontal branches of a tree), most of which travel parallel to the muscle fibers.





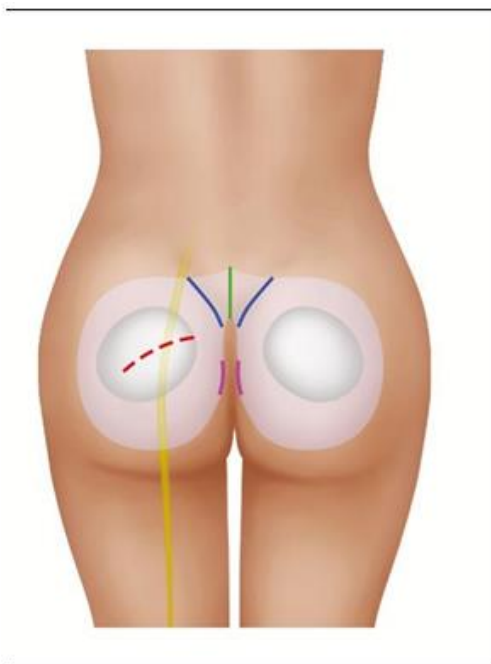
## Gluteoplasty Implants And Lipotransfer Technique

In surgical and body contouring praxis, the plastic surgeon effects the implant-pocket undermining of the gluteus maximus muscle by carefully separating the muscle fibers to avoid severing the pertinent blood vessels, which would interfere with the blood irrigation of the muscle tissue. Therefore, to create an implant-pocket, either for a gluteal prosthesis or for lipoinjection, a low-angle muscle-dissection is performed in order to avoid the risk of severing any major branch, superior or inferior, of the gluteal artery, which travels very close to the sacrum and to the sacrotuberous ligament.

### Surgical Procedures

#### Medical treatment

The resolution of the defects and deformities of the gluteal region muscles of the human body cannot be realized with medical therapy. For example, a treatment with cellulite-diminishing cream is ineffective for correcting the



Augmentation with a gluteal implant is the method most effective for enlarging the buttocks of the man or of the woman whose body possesses few stores of excess adipose fat in the lower portion of the trunk, the buttocks and thighs, the anatomic regions where the human body usually stores excess body fat.

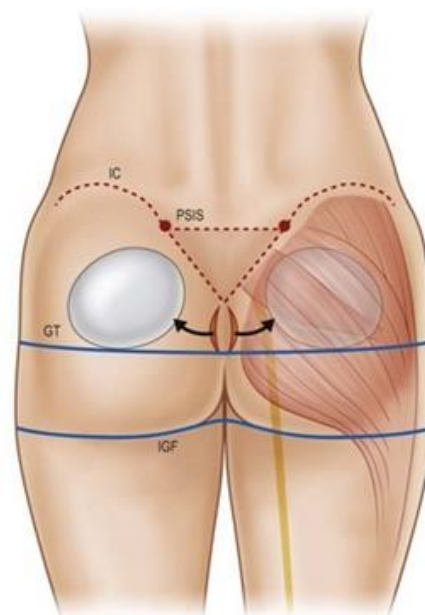
corresponding physical faults respectively presented by the man and by the woman patient. Is exercise a mitt also for the patients that need a real shape change?

### Surgical therapy

While the resolution of the defects and deformities of the gluteal region can be realized surgically, the assessment of the degree of severity of the injury organizes treatment therapies into three types: buttocks augmentation, buttocks reduction, and contour irregularity treatments that combine surgery and liposculpture (liposuction and lipotransfer).

### Treatments involving buttocks augmentation with implants

The augmentation of the buttocks is realized with a gluteal implant, which is emplaced under each gluteus maximus muscle; the insertion of the buttock prosthesis is through a midline incision (5–8-cm-wide) over the coccyx.



Due to the incision into the flesh of the tailbone muscles, the full healing of the augmented tissues can be approximately 6–8 months, during which the gluteal-muscle tissues relax, and the settled buttocks prostheses are integrated to the gluteal region.

## Gluteoplasty Implants And Lipotransfer Technique

The implantation procedure can be performed upon a patient who is either sedated or anaesthetized, either under general anesthesia or under local anesthesia. The usual operating time for a buttock's augmentation procedure is approximately 2 hours. The procedure can be managed either as an overnight in-patient treatment or as a hospital outpatient procedure. Given the nature of the surgical incisions, the therapeutic management of post-surgical pain, normal tissue-healing usually require a 4-6-week convalescence time, after which the patient resumes his or her normal-life activities.

### Lipotransfer

The augmentation and contouring of the buttocks with autologous-fat transfer (lipoinjection) therapy is realized with the excess adipose tissue harvested from the abdomen, flanks, and thighs of the patient. *In 1985 Dr. ABEL CHAJCHIR, a Argentinian Plastic Surgeon, described the*

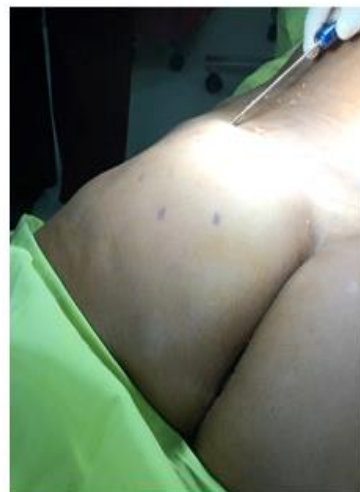

Therefore, depending upon the health of the patient, the convalescence period allows him or her to resume normal life activities at 2-post-operative days, and the full spectrum of physical activities at 2 post-operative weeks. Furthermore, the liposuction harvesting of the patient's excess body fat improves the aesthetic appearance of the fat donor-sites. Nonetheless, physiologically, the

*technique, naming it "fat injection" for the first time.*

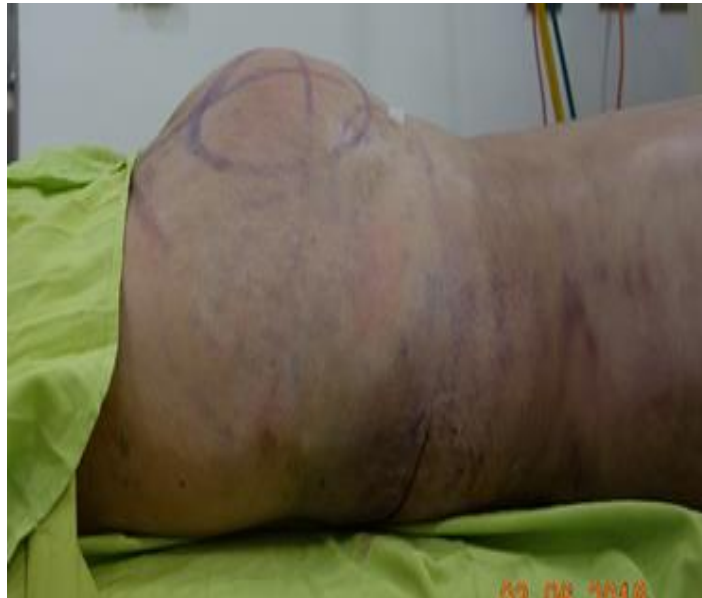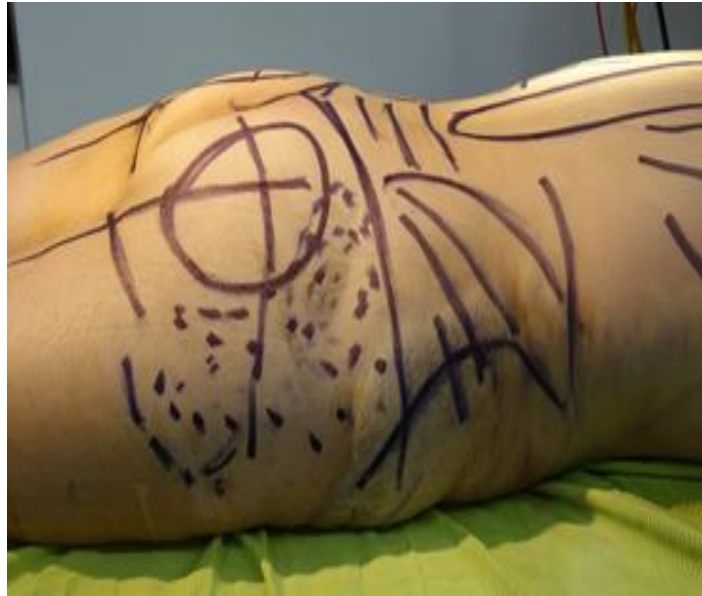The gentle liposuction applied to harvest the autologous fat minimally disturbs the local tissues, especially the connective-tissue layer between the skin and the immediate subcutaneous muscle tissues. Then, the harvested fat is injected to the pertinent body area of the gluteal region, through a fine-gauge cannula inserted through a small incision, which produces a short and narrow scar. Lipoinjection contouring and augmentation with the patient's own body fat avoids the possibility of tissue rejection and is physically less invasive than buttocks-implant surgery.

Lipotransfer increase contour with the transfer of autologous fat. Fat is injected to improve body area of the gluteal region with a 4 mm blunt tip cannula and a pump machine inserted through small incision avoiding the possibility of fat damage.



human body's normal, health-management chemistry reabsorbs (break down and eliminate) some of the injected adipose tissue, diminishing the final augmentation. According to the degree of decreased volume and contour caused by the fat reabsorption, the patient might require additional sessions of fat-transfer therapy to achieve the desired size, shape, and contour of the buttocks.

## Gluteoplasty Implants And Lipotransfer Technique



### Results

The result appears generally after six months and sometimes even a year after the procedure, depending on the restoration ability of the tissue and the patient's body. The patient with lipotransfer normally requires approximately six months and sometimes over a year before the results are visible. For both procedures, it is approximately after one month, that the aesthetic results can be noticed in the corrected areas.

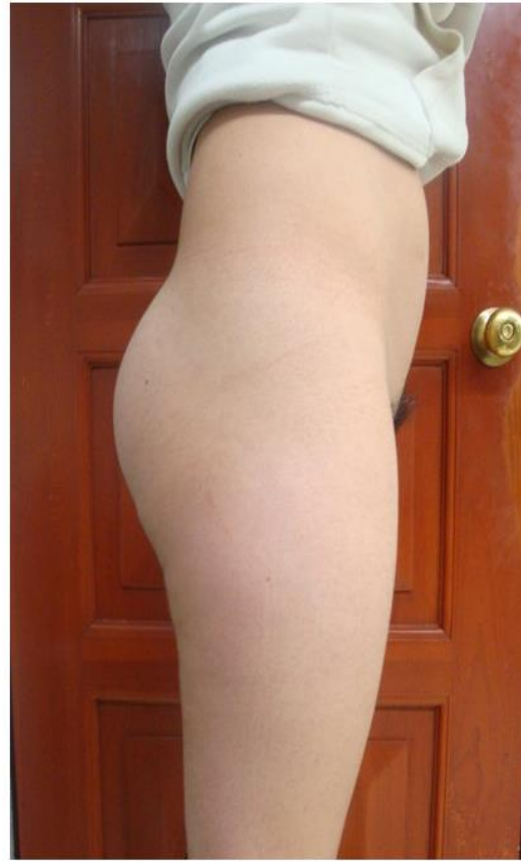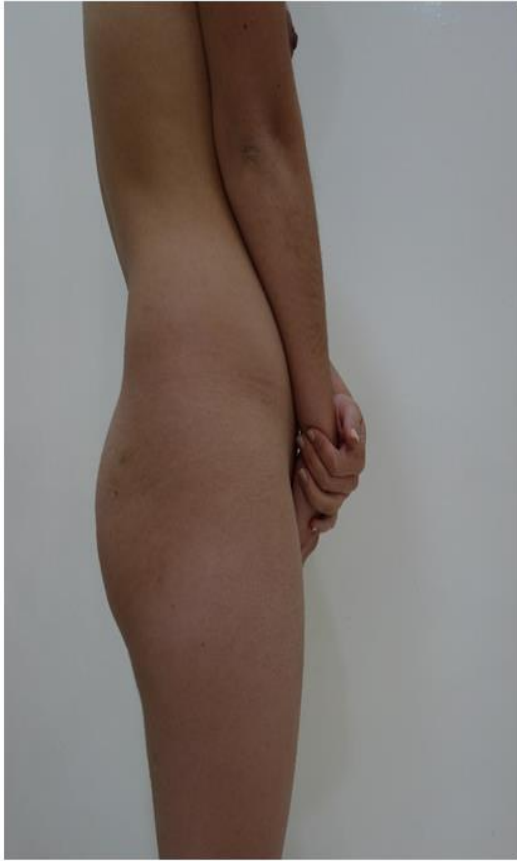The patient is advised to wear a compression garment to contain the swelling and to immobilize

the corrected tissues, so they heal as an anatomical unit of the gluteal region. In addition, it facilitates the contraction of new skin and helps resolve unevenness, wrinkles in the skin, and localized swelling. The application of massages and ultrasound treatments is not recommended as it may facilitate the reduction of postoperative results.

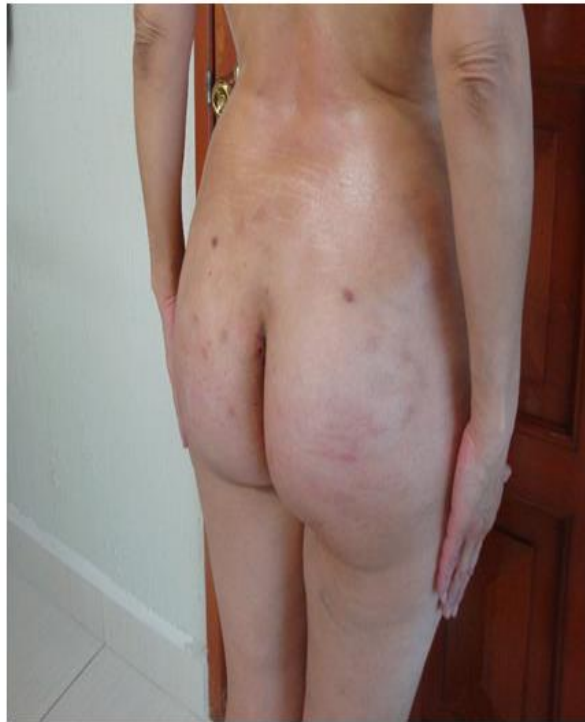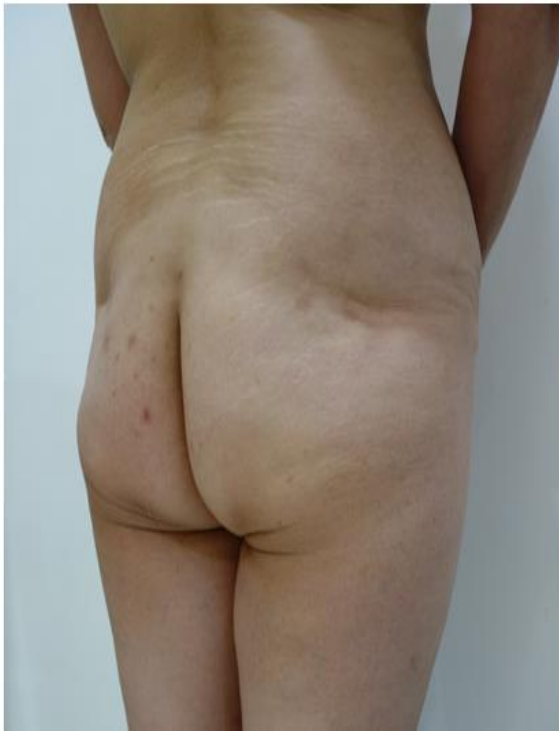33 YEARS OLD PATIENT WHO GET AN 300 CC SMOOTH ROUND IMPLANTE

AND 700 CC OF FAT IN EACH BUTTOCK

## Gluteoplasty Implants And Lipotransfer Technique

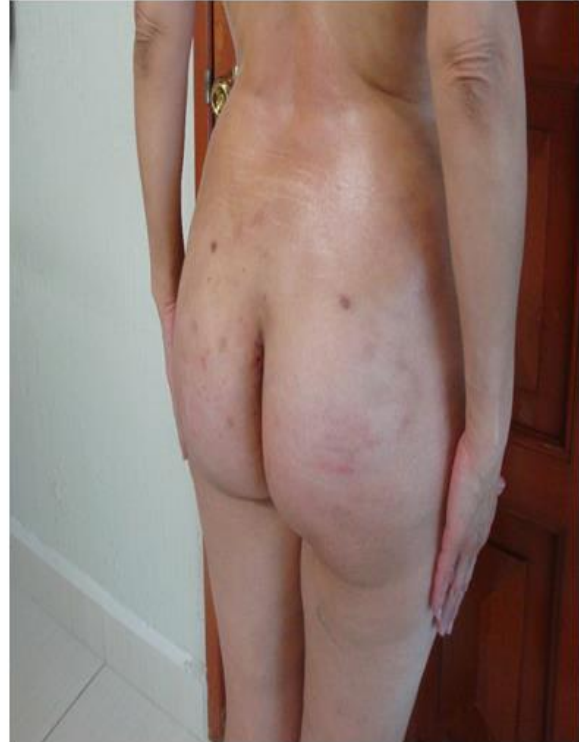
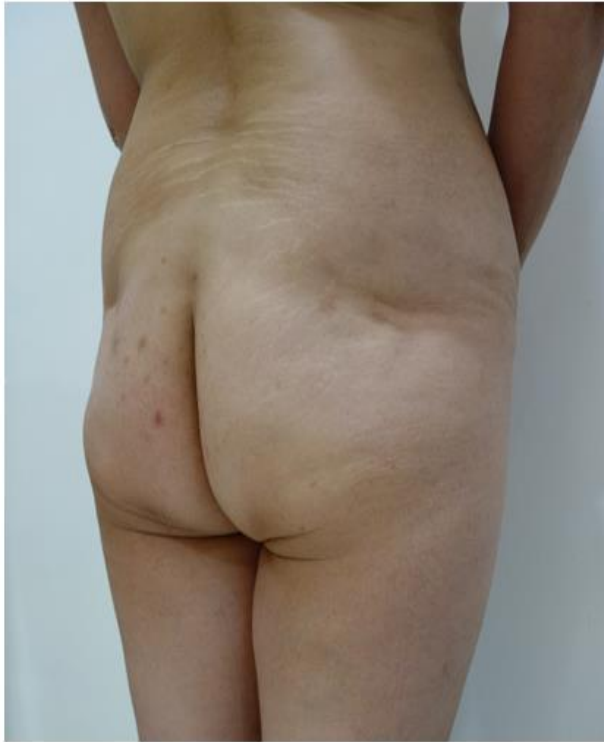
42 YEARS OLD PATIENT WHO GET AN 360 CC SMOOTH ROUND IMPLANTE AND 1200 CC OF FAT IN EACH BUTTOCK





## Gluteoplasty Implants And Lipotransfer Technique



### Complications

The surgical contouring of the human body presents possible medical complications such as: psychological issues, having body image unrealistic expectations of an aesthetic improvement; physical issues, uneven contour. Besides, the patient could undergo through physiologic toxic reactions to the anesthetic and the tumescent drugs.

The patient could also suffer from paresthesia, meaning localized areas of perduring numbness in the corrected portion(s) of the gluteal region. The medical complications possible to a surgical buttock's augmentation procedure include infection, surgical-wound dehiscence that exposes the implant, revision surgery, rupture of the implant, seroma, capsular contracture, asymmetry of the corrected area, shifting of the implant, surgical over-correction, injury of the sciatic nerve, and paresthesia.

The medical complications possible to a liposculpture buttocks augmentation include the bodily resorption of some of the injected adipose fat cells, asymmetric contour of the corrected body area, an irregular contour to the body, seroma, abscess (pus enclosed by inflamed tissue),

cellulitis (subcutaneous connective-tissue inflammation).

### Conclusion

Implant prosthesis and lipotransfer improves the anatomical curvature of the gluteal region, project more the gluteal area and achieve the side part of the buttock (feminine) and mark a difference compared to men shape.

### Bibliographe

1. Roberts TL III, Toledo LS, Badin AZ. Augmentation of the buttocks by micro fat grafting. *Aesthet Surg J.* 2001; 21:311319
2. Mendieta CG. Gluteal reshaping. *Aesthet Surg J.* 2007; 27:641655.
3. Rosique RG, Rosique MJ, De Moraes CG. Gluteoplasty with autologous fat tissue: Experience with 106 consecutive cases. *Plast Reconstr Surg.* 2015; 135:13811389.
4. Singh D. Universal allure of the hourglass figure: An evolutionary theory of female physical attractiveness. *Clin Plast Surg.* 2006; 33:359370.
5. Heidekrueger PI, Sinno S, Tanna N, et al. The ideal buttock size: A sociodemographic morphometric evaluation. *Plast Reconstr Surg.* 2017; 140:20e32e.

## Gluteoplasty Implants And Lipotransfer Technique

6. Wong WW, Motakef S, Lin Y, Gupta SC. Redefining the ideal buttocks: A population analysis. *Plast Reconstr Surg.* 2016; 137:17391747.
7. Lewis DMG, Russell EM, Al-Shawaf L, Buss DM. Lumbar curvature: A previously undiscovered standard of attractiveness. *Evol Hum Behav.* 2016; 36:345350.
8. Roberts TL III, Weinfeld AB, Bruner TW, Nguyen K. "Universal" and ethnic ideals of beautiful buttocks are best obtained by autologous micro fat grafting and liposuction. *Clin Plast Surg.* 2006; 33:371394.
9. Hafezi F, Naghibzadeh B, Nouhi AH, Salimi A, Naghibzadeh G, Mousavi SJ. Epidural anesthesia as a thromboembolic prophylaxis modality in plastic surgery. *Aesthet Surg J.* 2011; 31:821824.
10. Moore JH Jr, Kolaczynski JW, Morales LM, et al. Viability of fat obtained by syringe suction lipectomy: Effects of local anesthesia with lidocaine. *Aesthetic Plast Surg.* 1995; 19:335339.
11. Keck M, Zeyda M, Gollinger K, et al. Local anesthetics have a major impact on viability of preadipocytes and their differentiation into adipocytes. *Plast Reconstr Surg.* 2010; 126:15001505.
12. Ozsoy Z, Kul Z, Bilir A. The role of cannula diameter in improved adipocyte viability: A quantitative analysis. *Aesthet Surg J.* 2006; 26:287289.
13. Erdim M, Tezel E, Numanoglu A, Sav A. The effects of the size of liposuction cannula on adipocyte survival and the optimum temperature for fat graft storage: an experimental study. *J Plast Reconstr Aesthet Surg.* 2009; 62:12101214.
14. Strong AL, Cederna PS, Rubin JP, Coleman SR, Levi B. The current state of fat grafting: A review of harvesting, processing, and injection techniques. *Plast Reconstr Surg.* 2015; 136:897912.
15. Sinno S, Wilson S, Brownstone N, Levine SM. Current thoughts on fat grafting: Using the evidence to determine fact or fiction. *Plast Reconstr Surg.* 2016; 137:818824.
16. Carpaneda CA, Ribeiro MT. Study of the histologic alterations and viability of the adipose graft in humans. *Aesthetic Plast Surg.* 1993; 17:4347.
17. Khouri RK Jr, Khouri RE, Lujan-Hernandez JR, Khouri KR, Lancerotto L, Orgill DP. Diffusion and perfusion: The keys to fat grafting. *Plast Reconstr Surg Glob Open* 2014;2: e220.
18. Toledo LS. Gluteal augmentation with fat grafting: The Brazilian buttock technique: 30 years' experience. *Clin Plast Surg.* 2015; 42:253261.
19. Murillo WL. Buttock augmentation: Case studies of fat injection monitored by magnetic resonance imaging. *Plast Reconstr Surg.* 2004; 114:16061614; discussion 16151616.
20. Wolf GA, Gallego S, Patrón AS, et al. Magnetic resonance imaging assessment of gluteal fat grafts. *Aesthetic Plast Surg.* 2006; 30:460468.
21. Swanson E. Prospective controlled study of buttock fat transfer using ultrasound and photographic measurements. *Plast Reconstr Surg Glob Open* 2016;4: e697.
22. Gonzalez R. Augmentation gluteoplasty: The XYZ method. *Aesthetic Plast Surg.* 2004; 28:417425.
23. Mofid MM, Gonzalez R, de la Peña JA, Mendieta CG, Senderoff DM, Jorjani S. Buttock augmentation with silicone implants: A multicenter survey review of 2226 patients. *Plast Reconstr Surg.* 2013; 131:897901.
24. Sinno S, Chang JB, Brownstone ND, Saadeh PB, Wall S Jr. Determining the safety and efficacy of gluteal augmentation: A systematic review of outcomes and complications. *Plast Reconstr Surg.* 2016; 137:11511156.

**How to Cite:** Arellano , A. ., Arellano , A. ., & Arellano , D. . (2022). **Gluteoplasty Implants and Lipotransfer Technique.** *Journal of Medical Research and Health Sciences*, 5(11), 2329–2338. <https://doi.org/10.52845/JMRHS/2022-5-11-2>